



**The human foot is a masterpiece of
engineering and a work of art.**

Leonardo da Vinci



Feet, the Joint Approach



North Downs Hospital

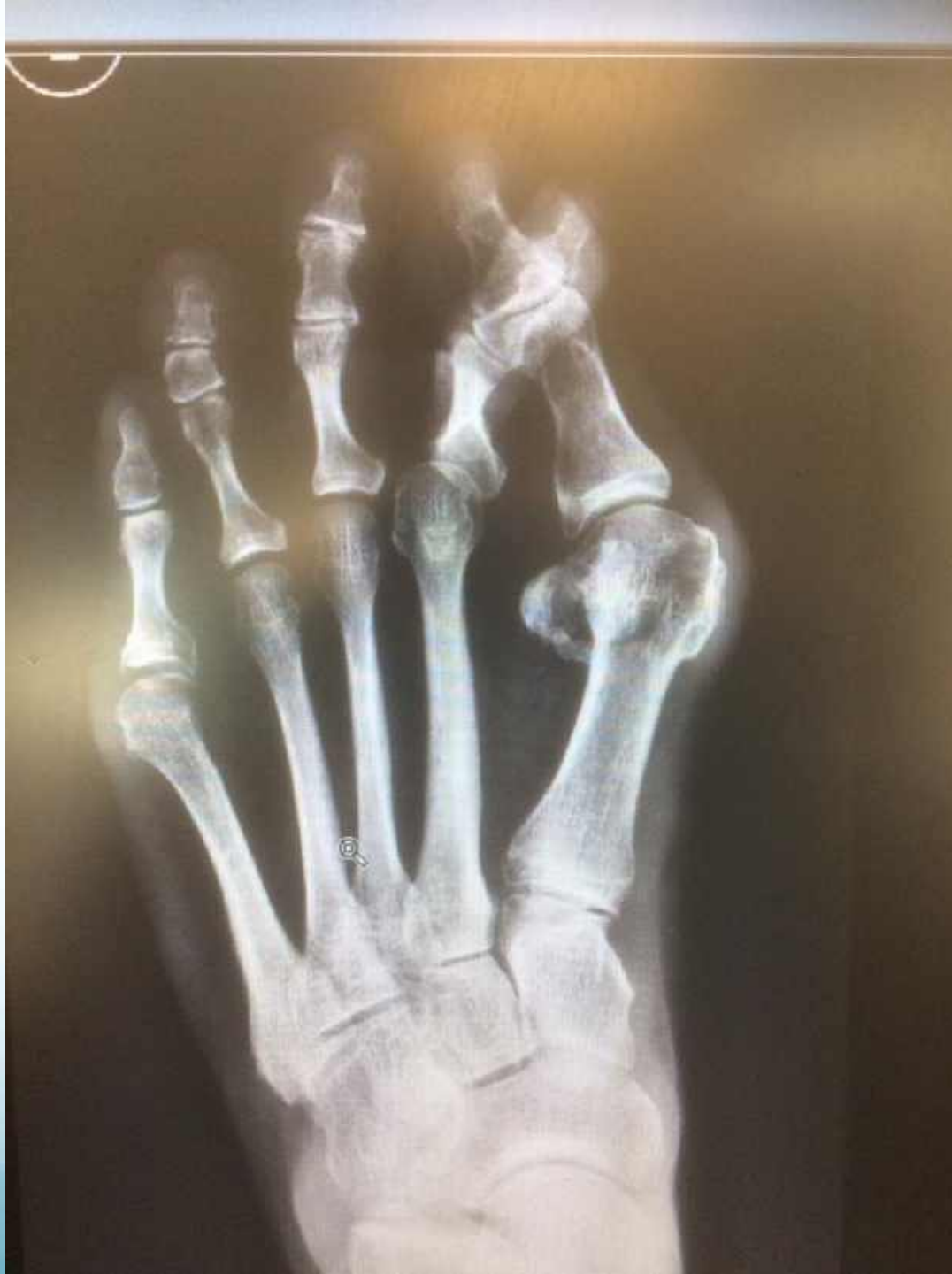Eoin Baldwin BSc(Hons) FRCPodS
Consultant Podiatric Surgeon

38 Years experience

Over 26,000 procedures

Adult and Paediatric





Common Foot Conditions

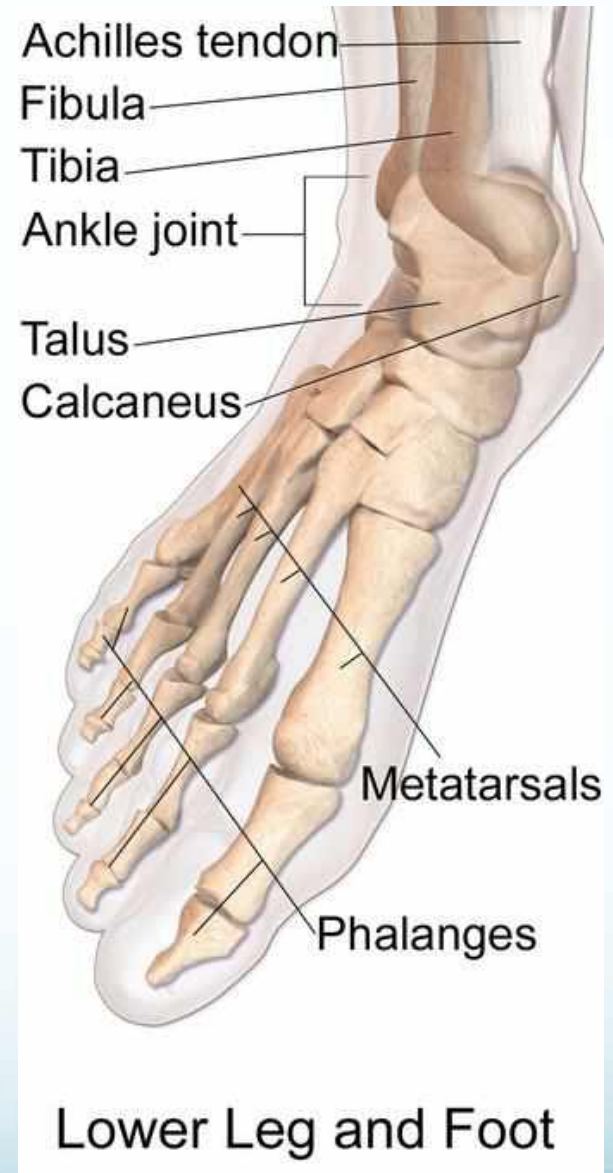
- Hallux Valgus (Bunion)
- Hallux Rigidus (Stiff Big toe)
- Hammer/ Claw toes
- Soft Tissue, eg Morton's Neuroma (Metatarsalgia)
- Tailors Bunions (Mini Bunion)
- Ganglion/cysts: Lumps and Bumps
- Ingrowing Toe Nails
- Children's foot problems
- Flat / High Arched feet

The FOOT

26 Bones

33 Joints

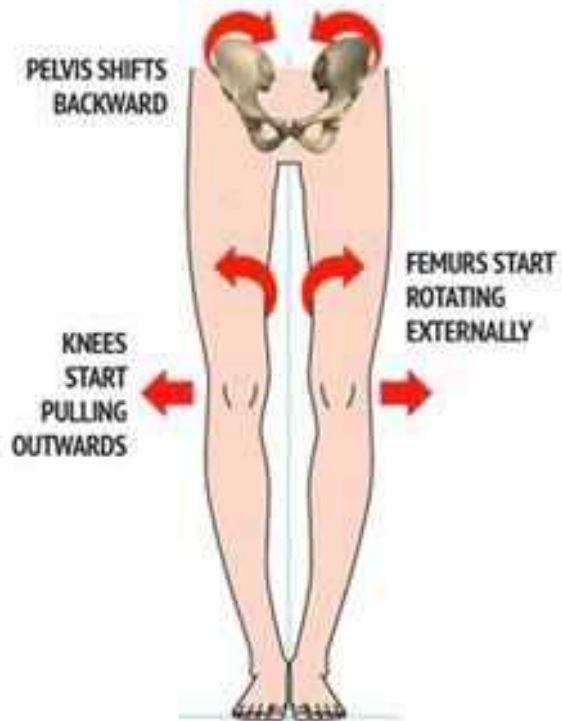
>100 muscles, Tendons and Ligaments



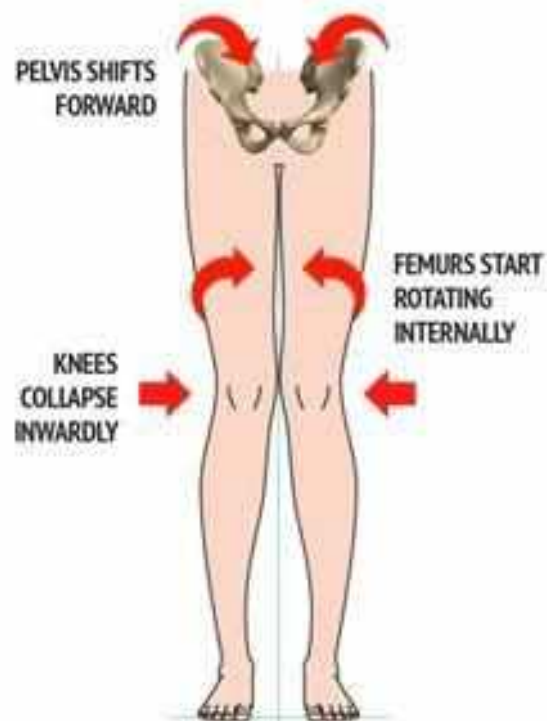
DANCING
LESSONS



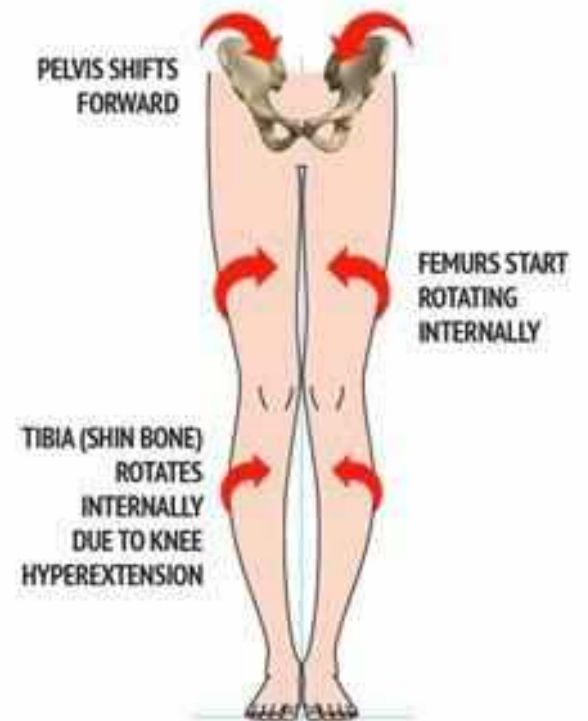
"There are only two things stopping
you from being a good dancer, Mr.
Jones. Your feet!"



BOW LEGS
(Genu Varum)



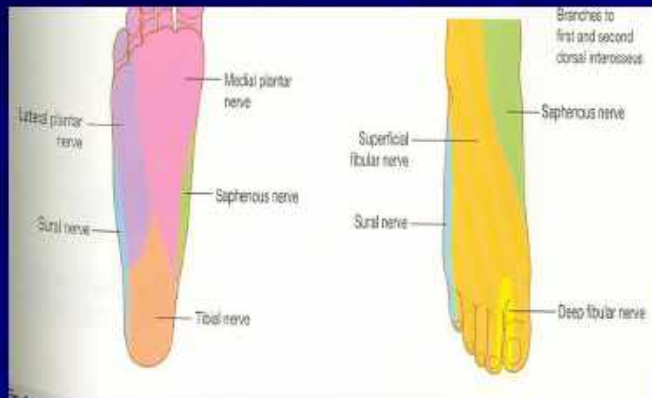
KNOCK-KNEES
(Genu Valgum)



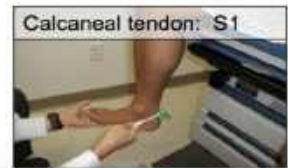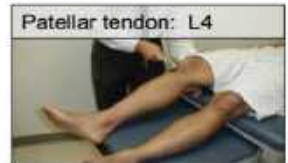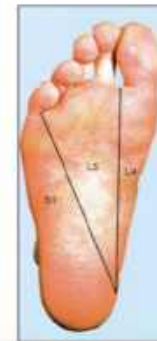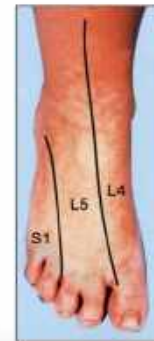
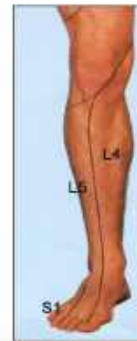FALSE CURVATURE
(Genu Recurvatum)

Neurological

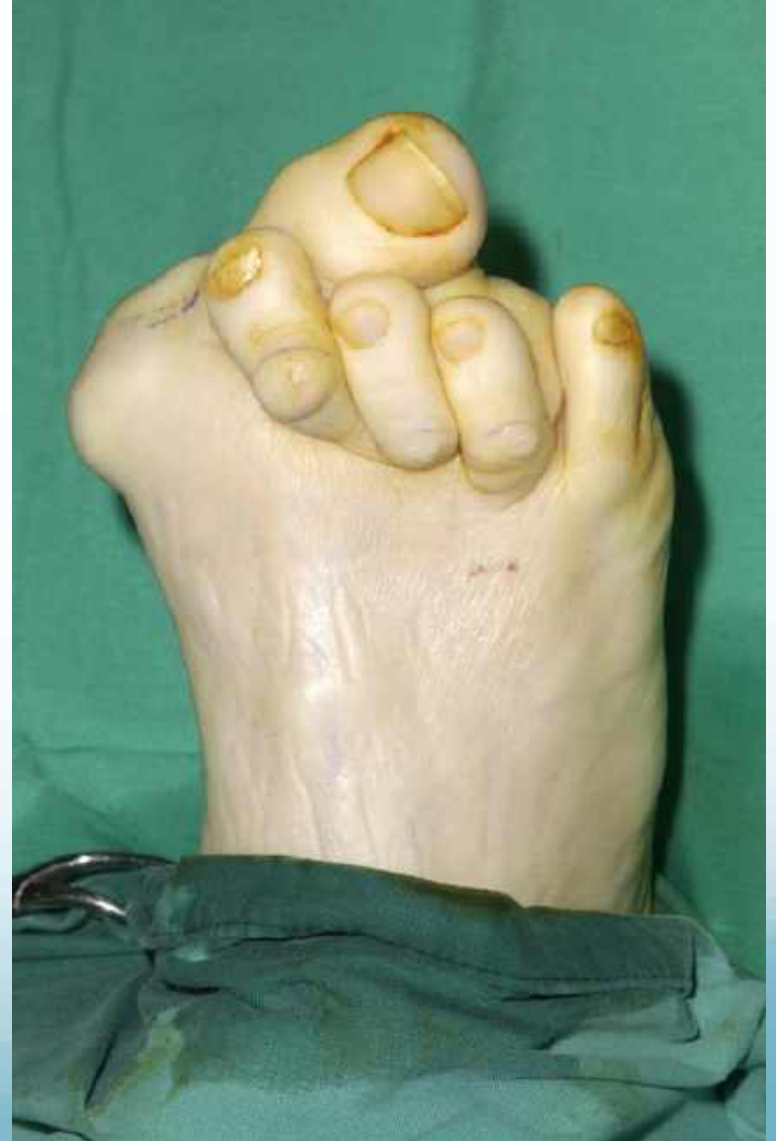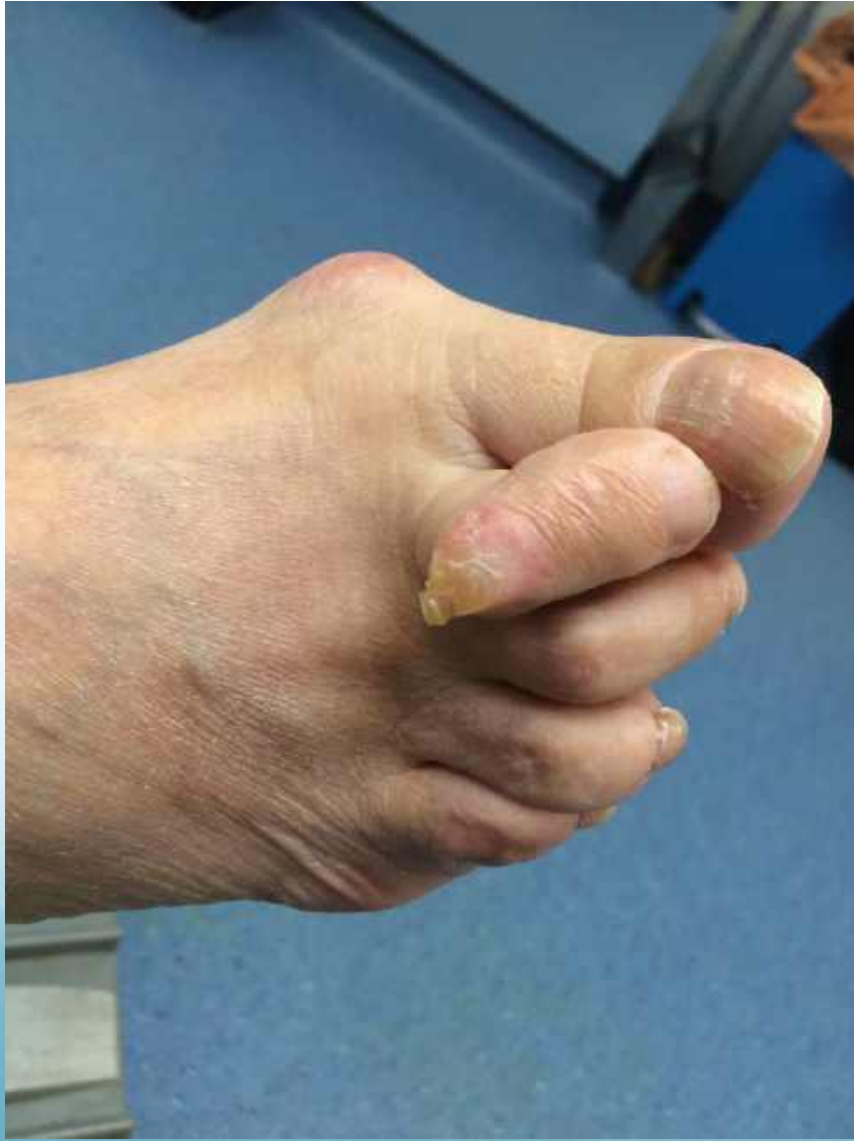Dermatomes of the foot



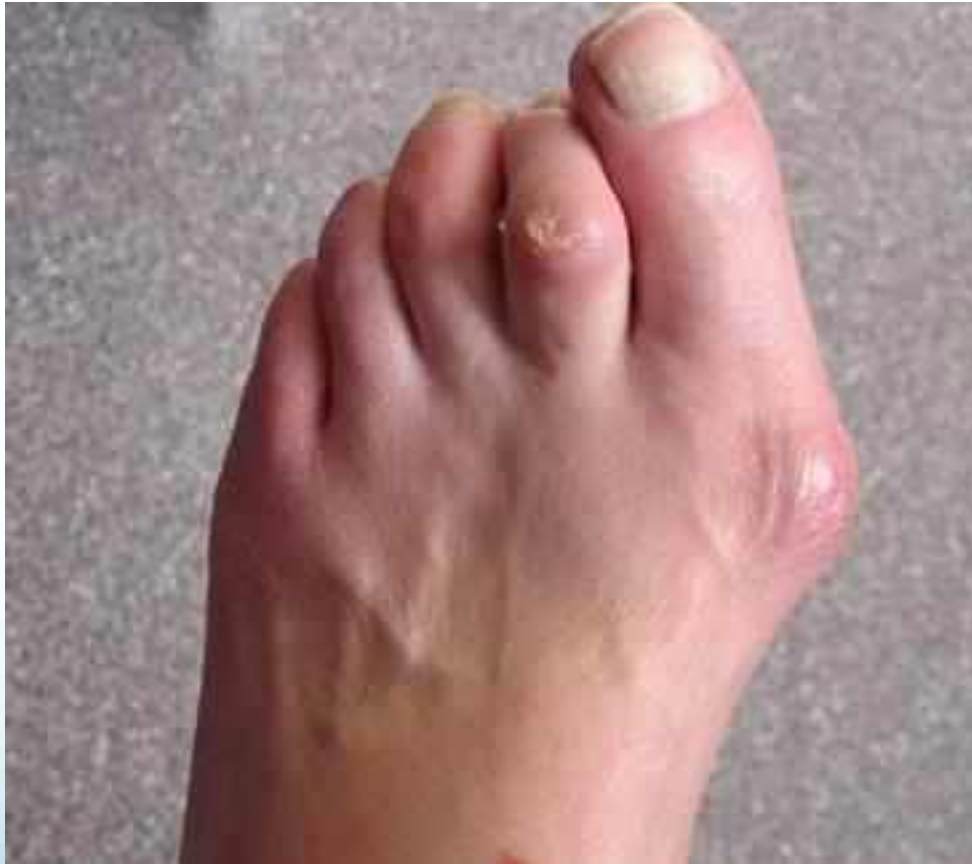IV disc	Roots affected	Dermatome Testing	Deep Tendon Reflex
L3/L4	L4	Medial leg & medial foot	Patellar tendon
L4/L5	L5	Lateral leg, dorsal foot	NONE
L5/S1	S1	Lateral foot	Calcaneal ("Achilles") tendon



Mechanical Vs Inflammatory

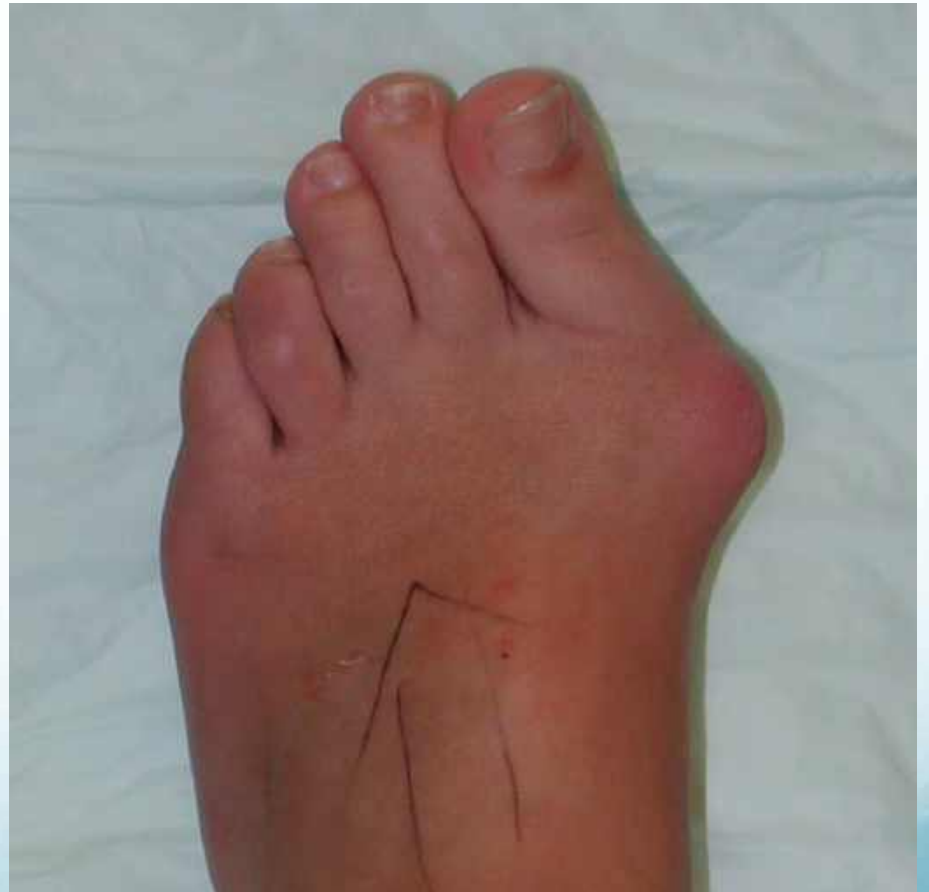

Bunion and Hammer Toe

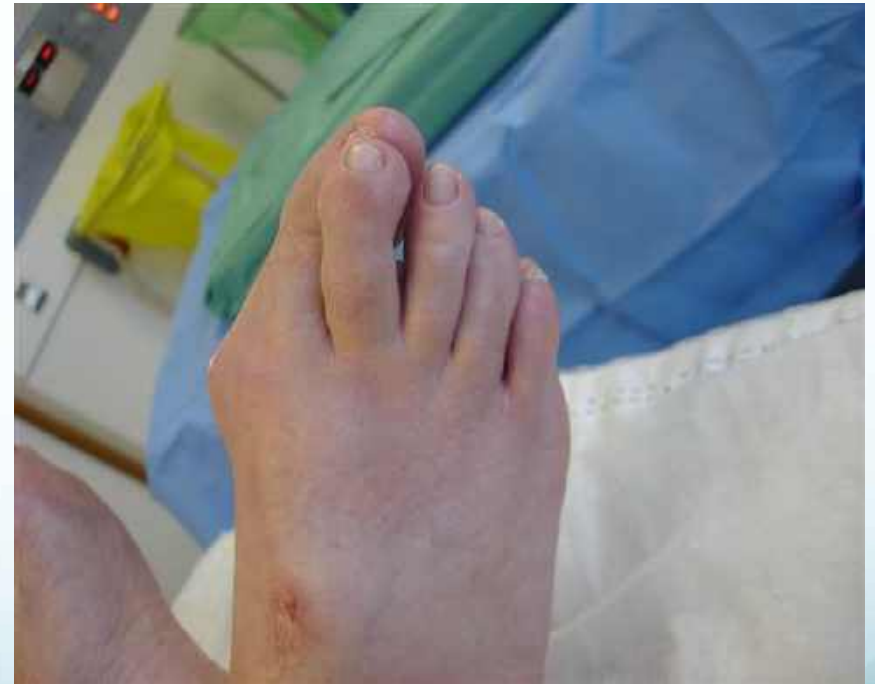
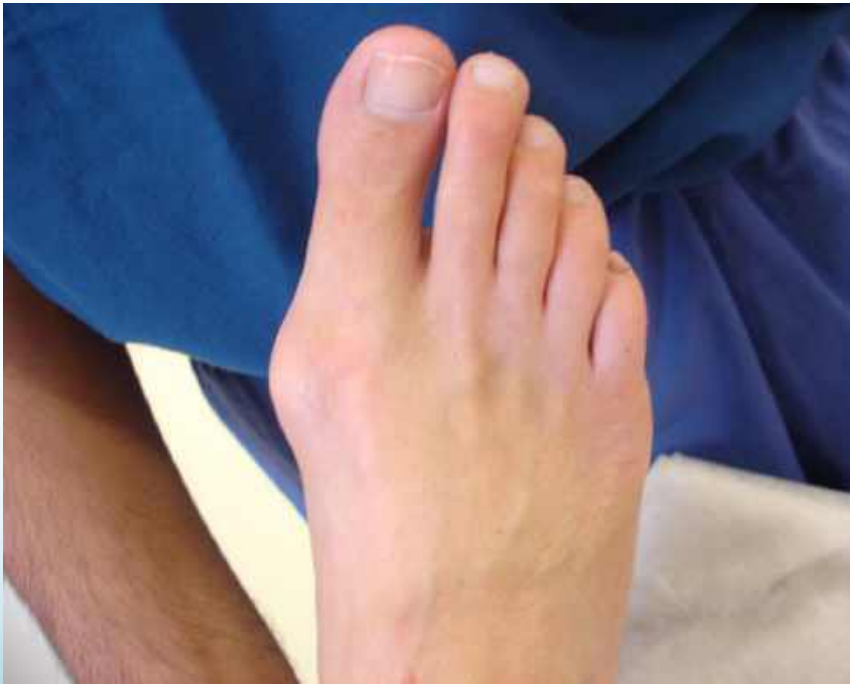
Hallux Valgus (Bunion)

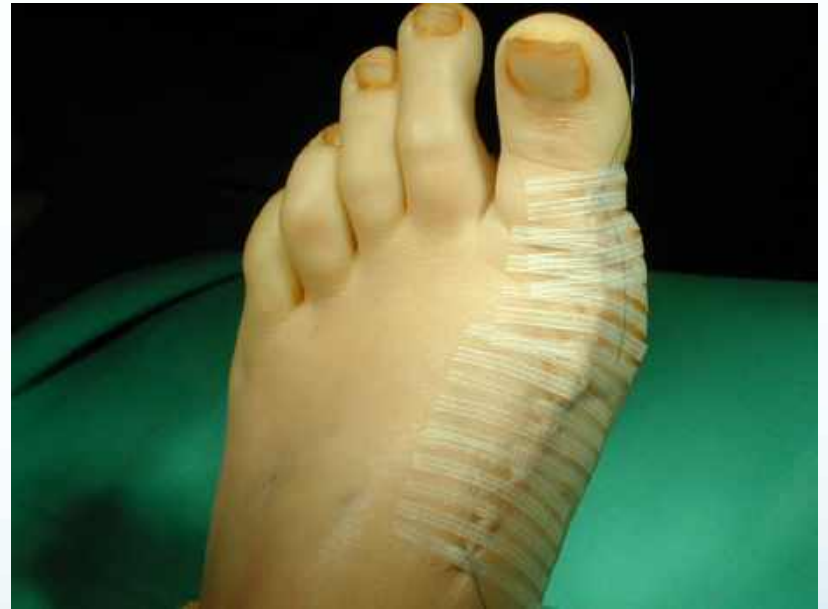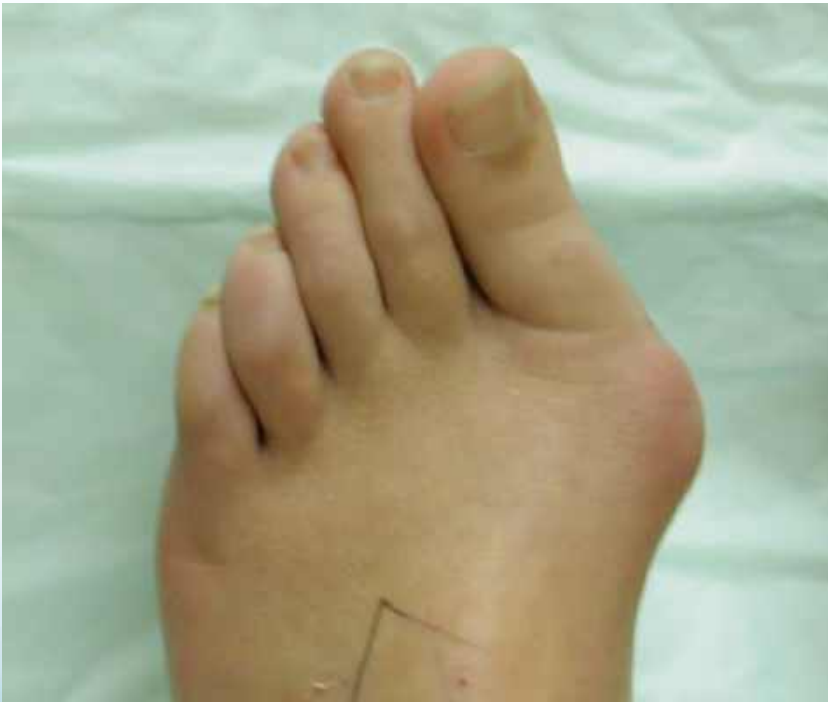- Hereditary
- Progressive Forefoot deformities
- Disabling
- Correctable
- Limited Conservative treatment



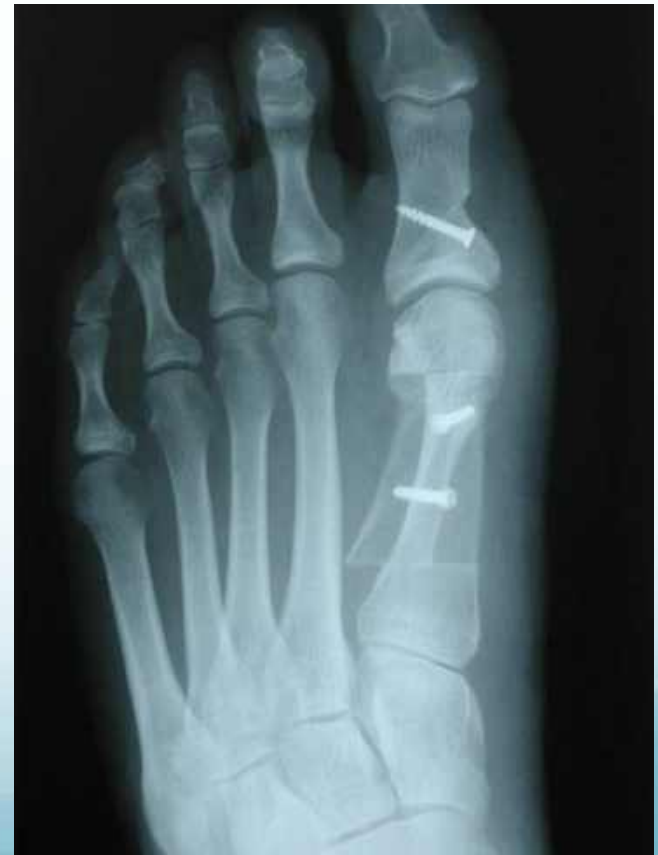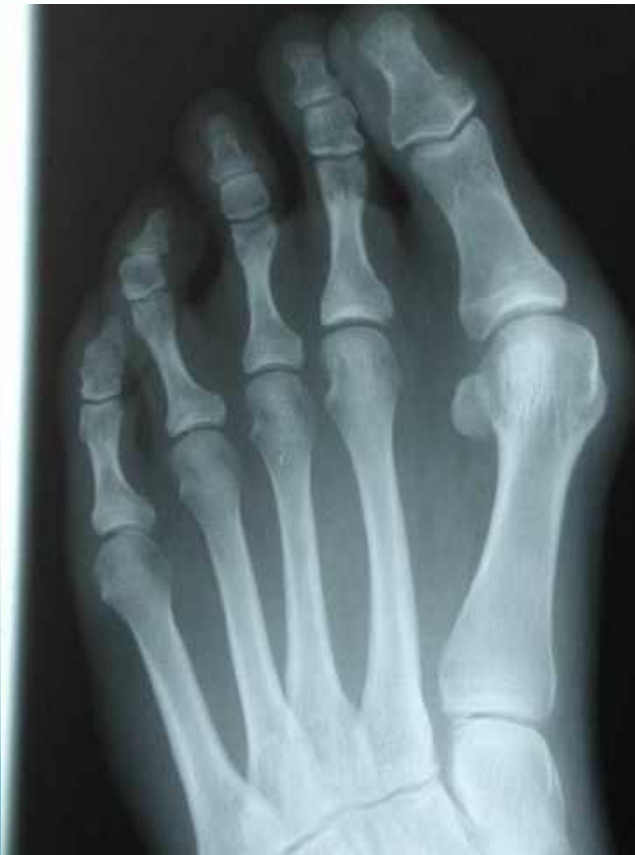It gets worse !!



Hallux Valgus, pre & post op



Scarf / Akin Osteotomies



Features to look for

- Painful medial bump with redness
- More impressive on weight bearing
- Pain from shoe pressure
- Good range of motion
- Big toe pressing on 2nd toe
- Hammer 2nd toe
- Present for years, can deteriorate over a few months

Hallux Valgus

- An boney , progressive deformity that “wrecks” the Forefoot
- Conservative measures do not help
 - Orthoses
 - Shoes
 - Physio / MSK
- Refer, before it deteriorates further

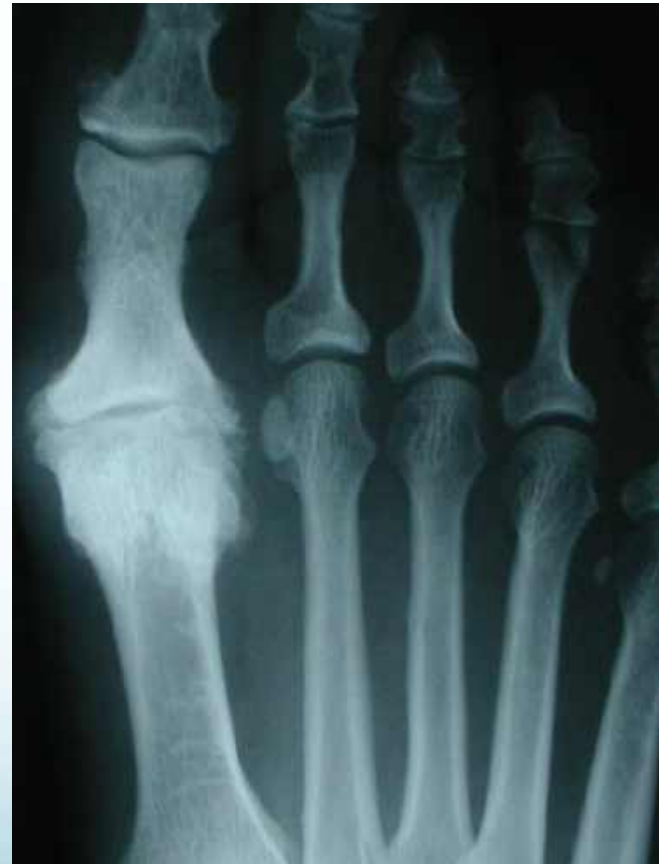Arthritis

- Hallux Rigidus or Stiff big Toe
- Toe joints
- Multiple Foot joints

Hallux Rigidus

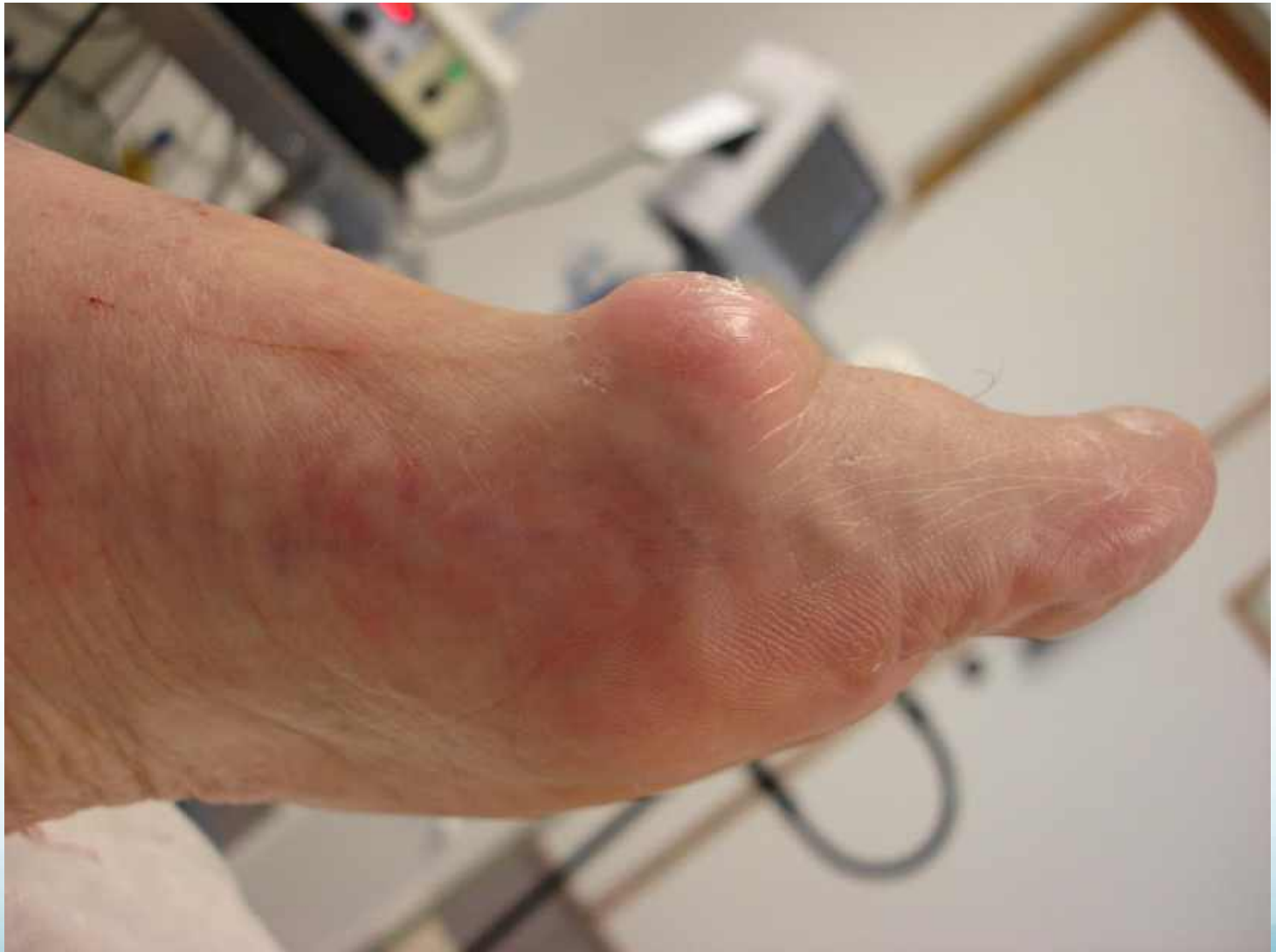Stiff Big Toe

- Hereditary
- Trauma, Systemic
- Disabling
- Conservative care
 - Shoes, Steroid
- Surgery

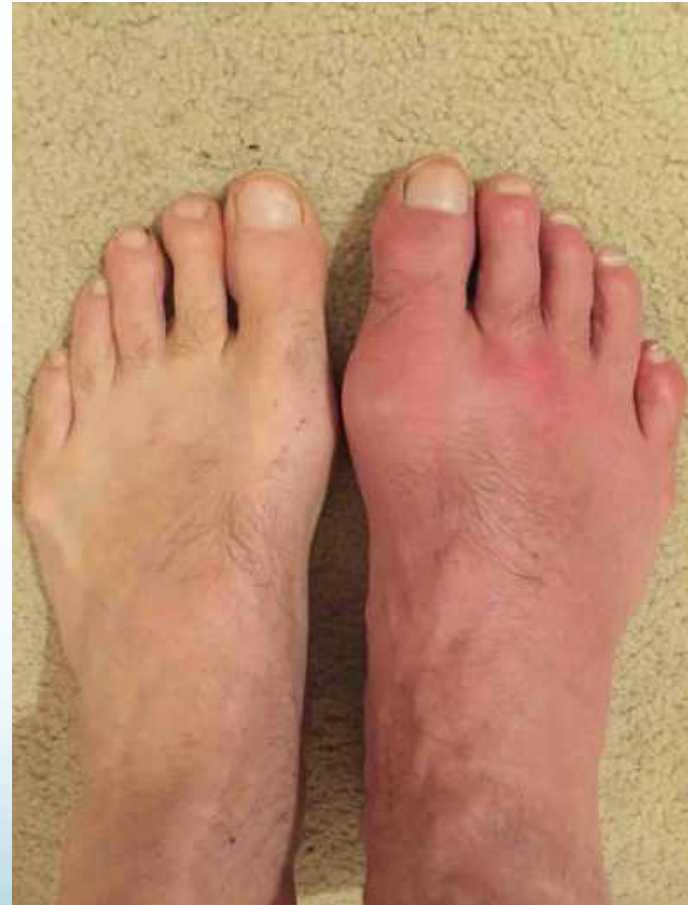
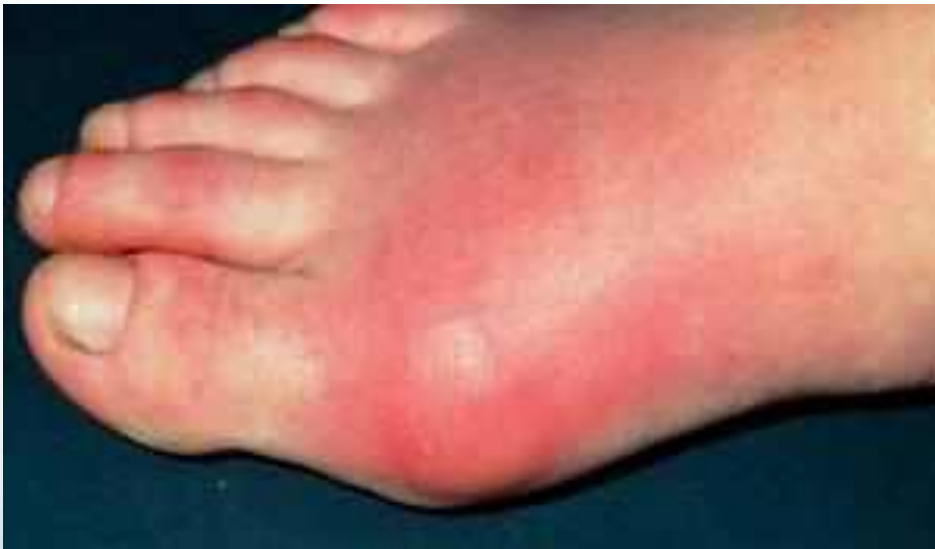
Features to look for

- Stiff big toe
- Dorsal bump extending across the joint
- The big toe is relatively straight
- Painful, worse with activity
- 2nd toe not usually involved
- Analgesic may relieve pain
- Steroid injection sometimes helps



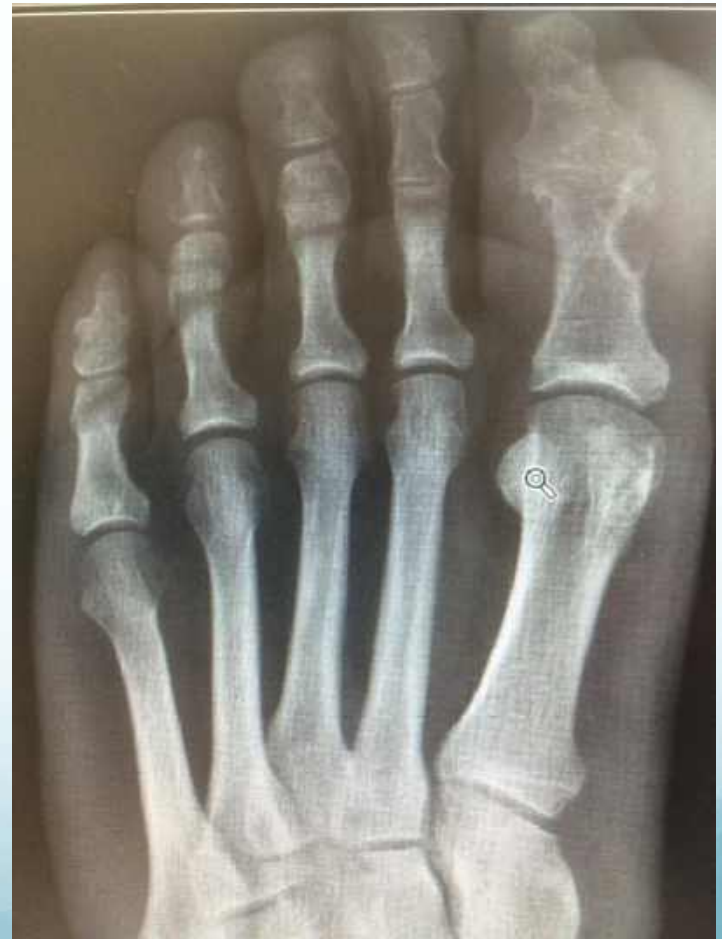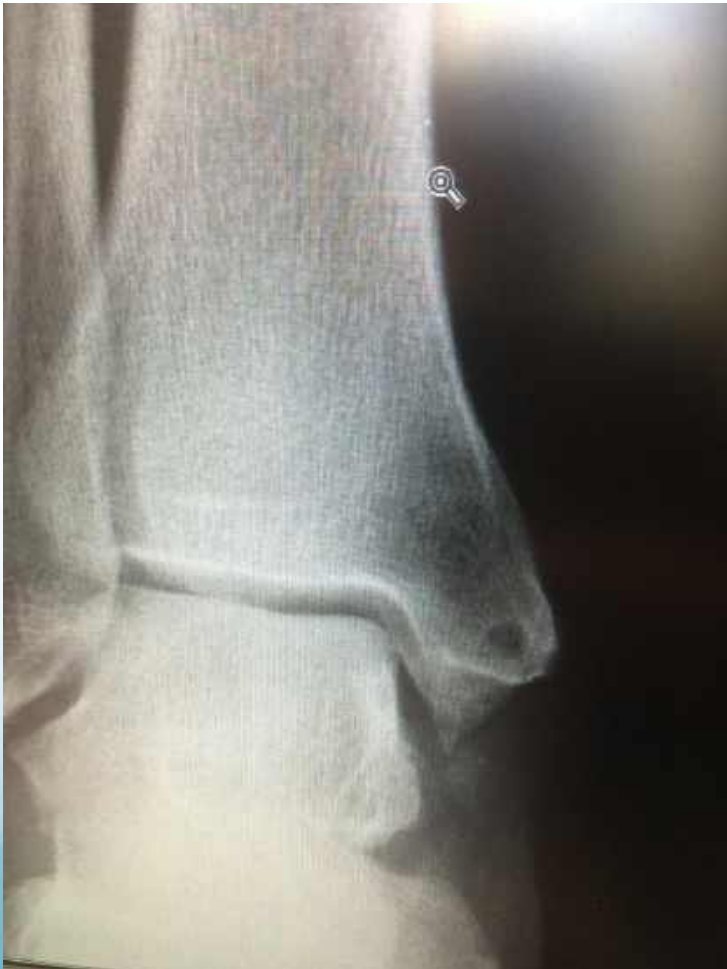Gout



Features to look for

- Extreme, intense pain in the big toe joint (75%)
- Inflammation of the joint and whole foot
- Sudden onset, often early morning
- Family history
- Analgesic may relieve pain but only marginally
- Low serum urate during acute phase

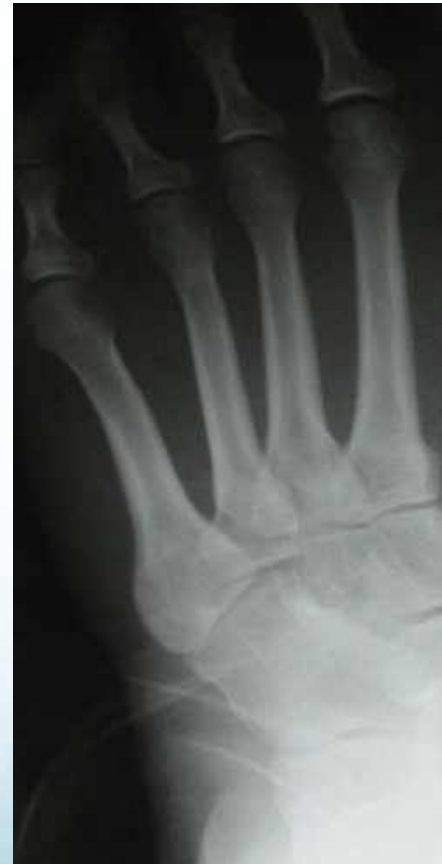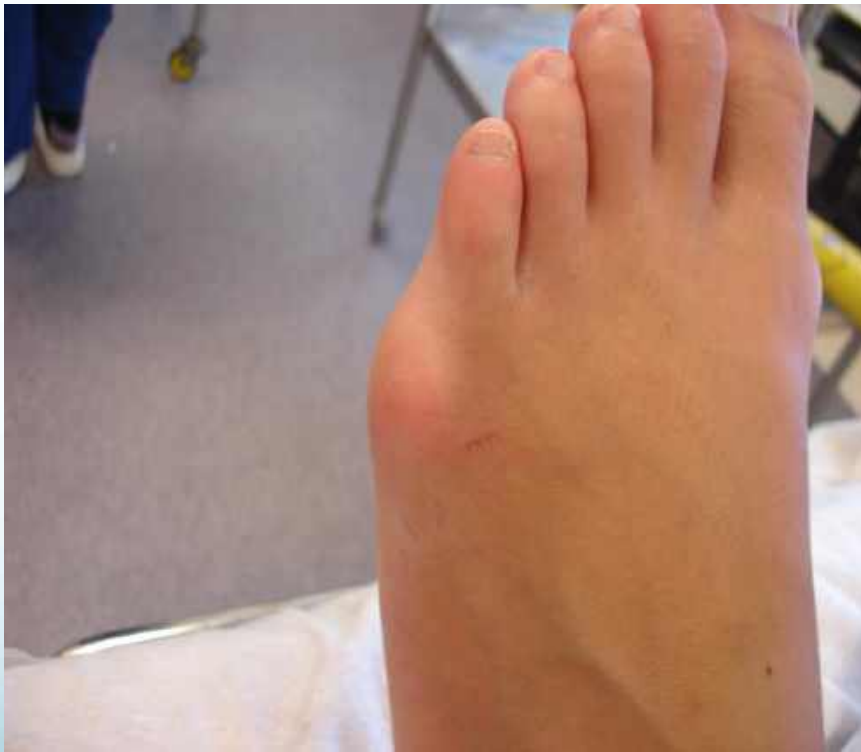Gout



Gout / Inflammatory Arthritis

- Joint Destructive
- Follow Rheumatology Guidelines
 - Treat acute stage
 - Prevent recurrence
 - Address comorbidities
 - Renal, diabetes, cardiovascular, depression, sleep apnoea
- Refer for Rheumatology Opinion Early
- Surgery if necessary

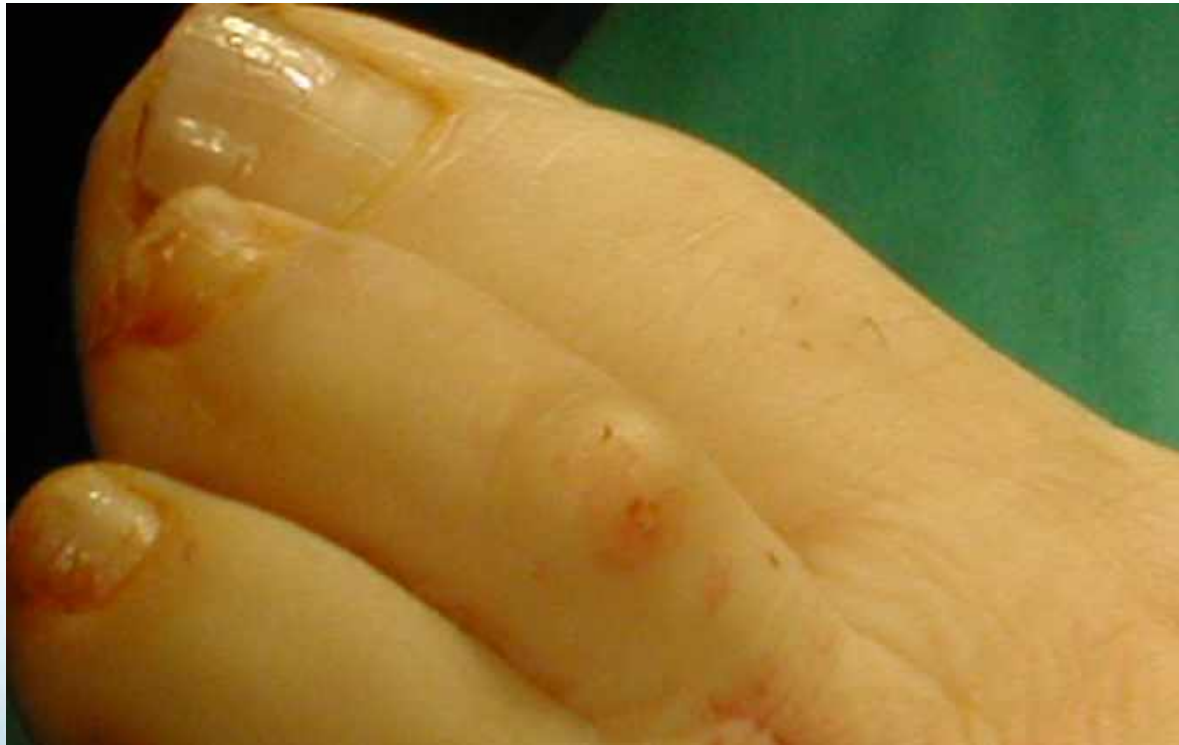Tailors Bunion



Features to look for

- Lateral side bump
- The 5th toe is leaning on the 4th
- Painful, worse with activity and footwear
- Avoiding shoe pressure may relieve pain
- Change footwear / refer for surgery to correct

Toes

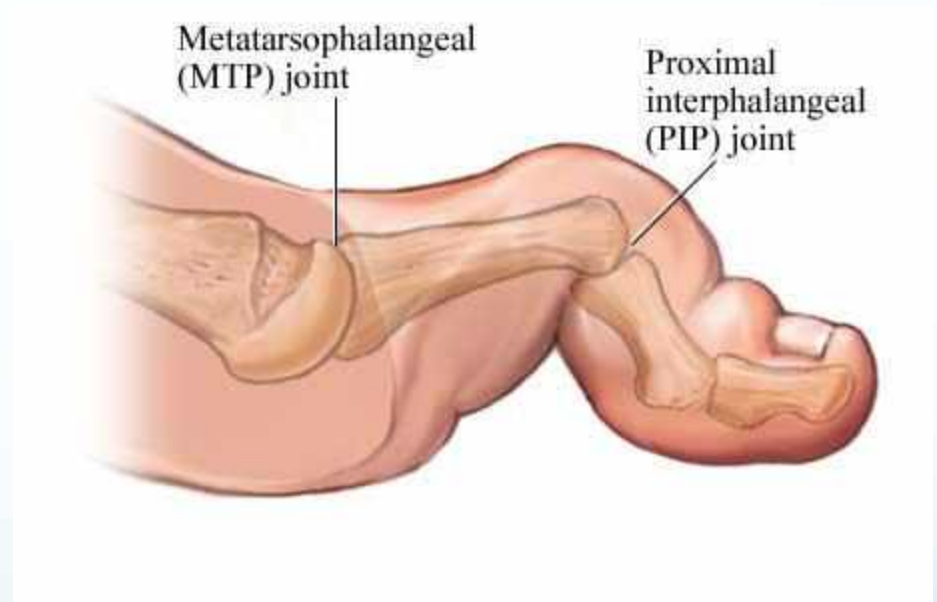


Features to look for

- Red “knuckles” on the toe(s)
- Rubbing on the upper of the shoe
- Often with a bunion present
- Pain in the ball of the foot, back from the 2nd toe
- Corns / hard skin / ulcers / blisters / infection
- Muroid cysts on the end joints

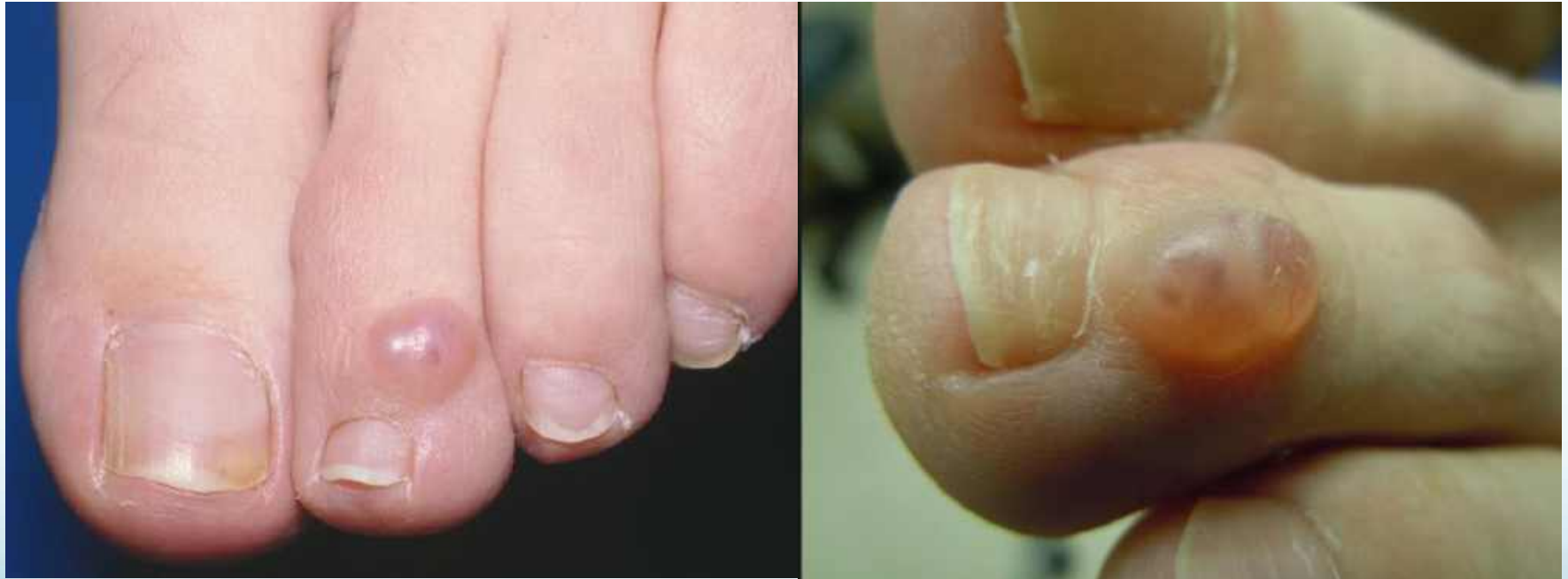Hammer Toe

- Multifactorial
- Retraction / deformity
- Shoe pressure
- Surgery to realign
- Conservative care
 - Shoes, Splints

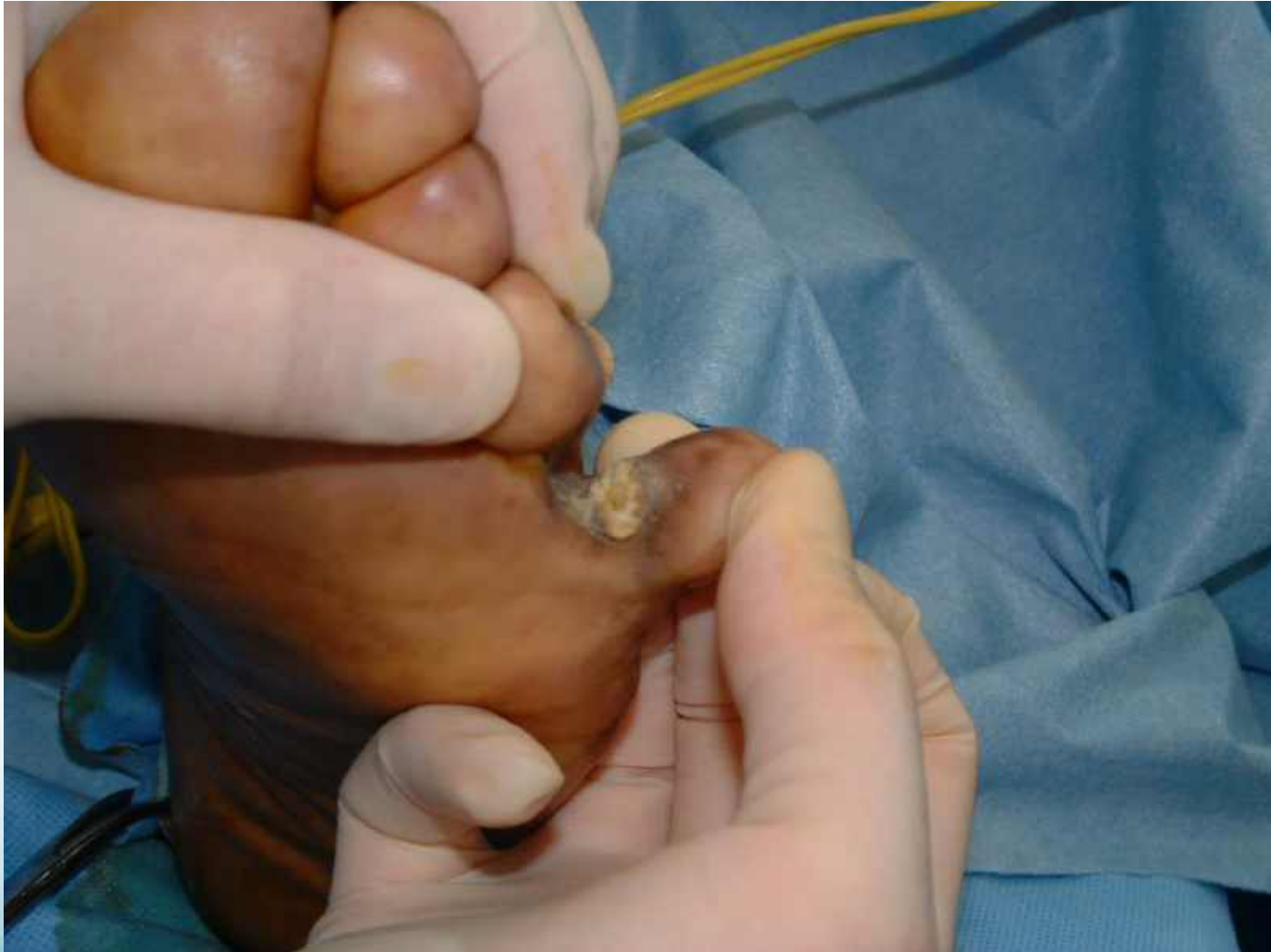

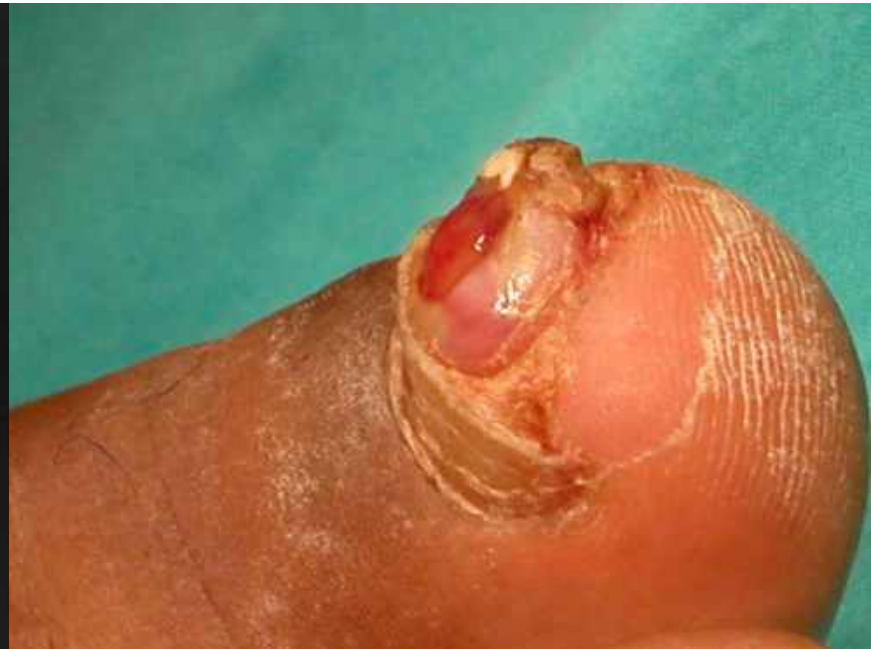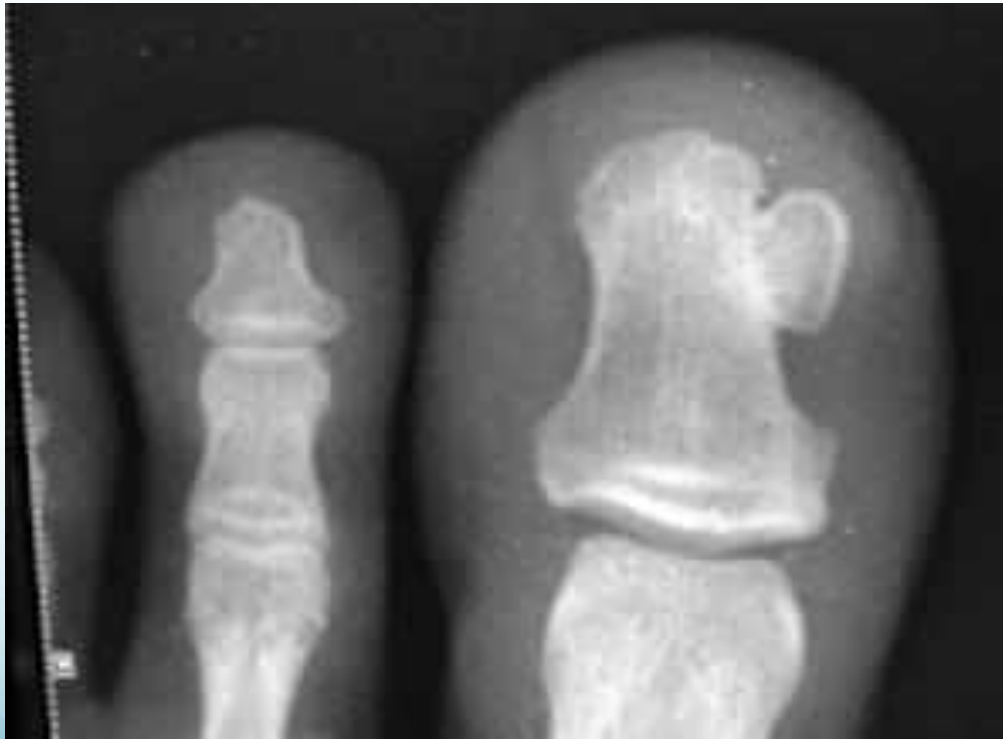Muroid Cyst

(on a Mallet toe)



Painful Corn between the Toes.



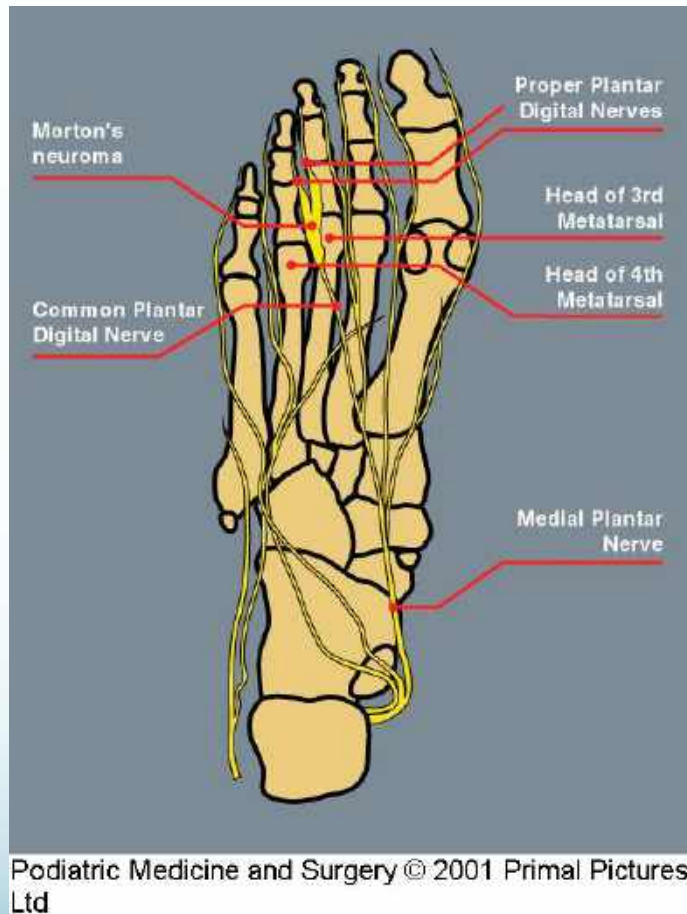


Morton's Neuroma

Features

- Pain, burning, tingling, numbness etc etc
- Ball of foot, planter pain
- Involves 2 or more central toes
- 3rd and 4th most common
- Regular pattern with weightbearing / shoes
- Rarely with toe deformities so.....
- Beware a hammer toe 2nd toe

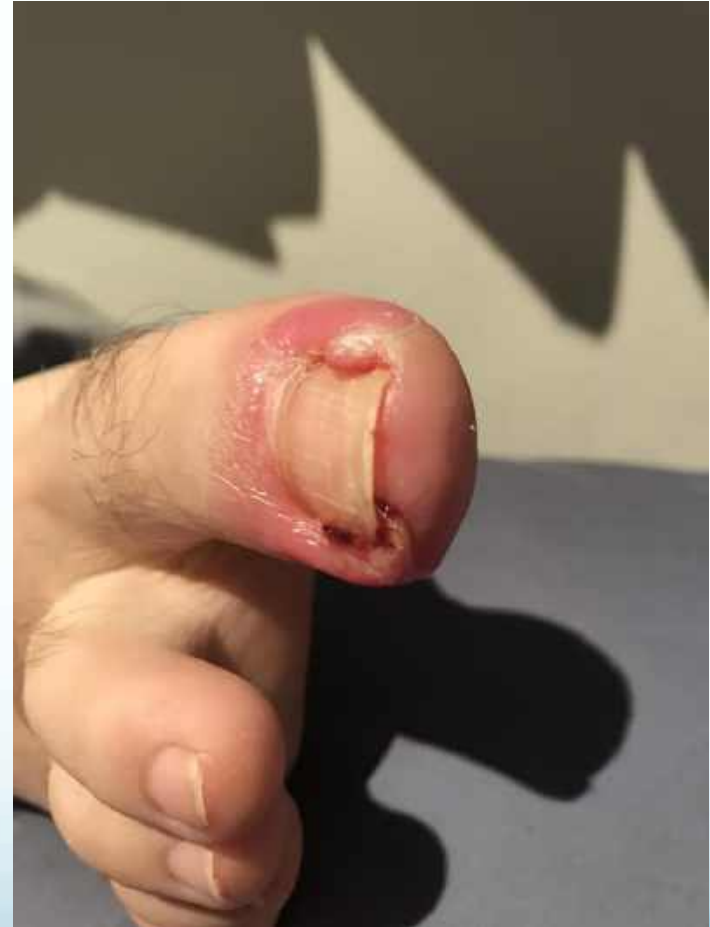Soft Tissue / Neuroma



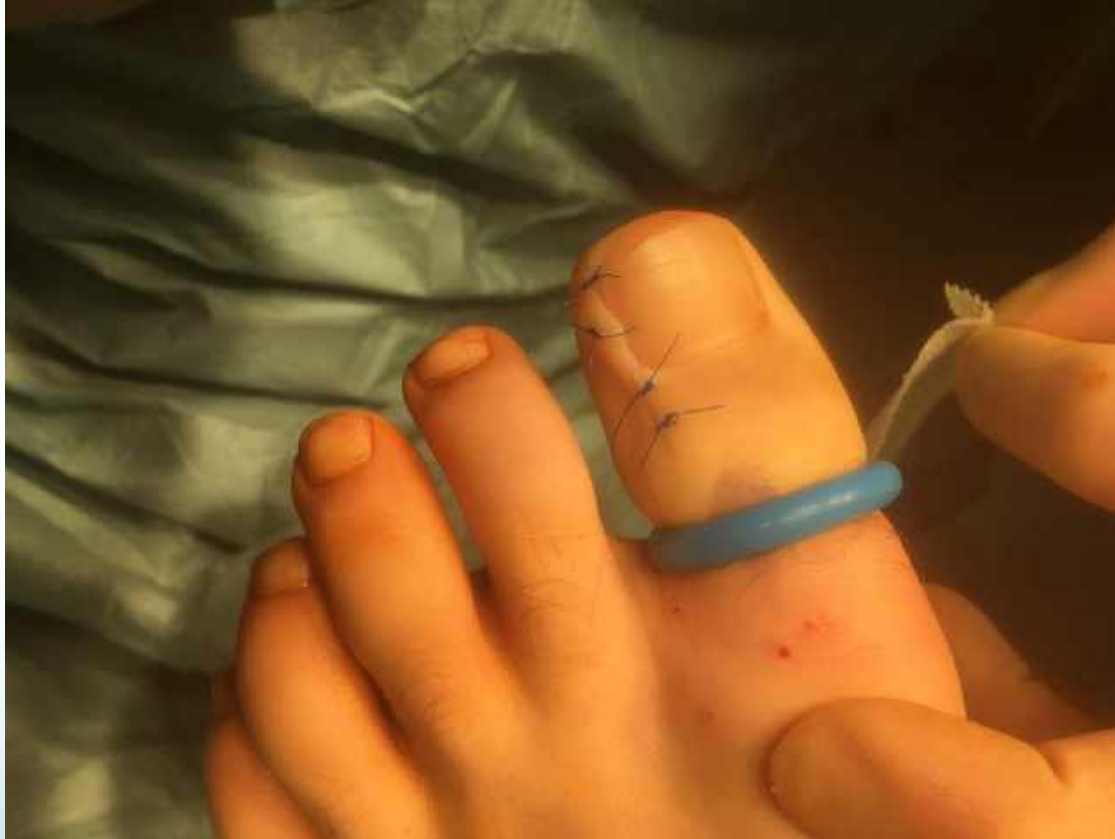- Ultra Sound Scan
 - Operator dependent
- Footwear
- Orthoses
- Guided Injection
 - Limited success
 - Must < 8mm
 - Bursa reduction
- Surgical removal
 - High success rates

Ingrowing Toenails

- Infected, Genetic, Duration
- Antibiotics
- Podiatry
 - Conservative care
 - Phenolisation
- Podiatric Surgery
 - Reconstructive
 - Best Cosmetic Outcome

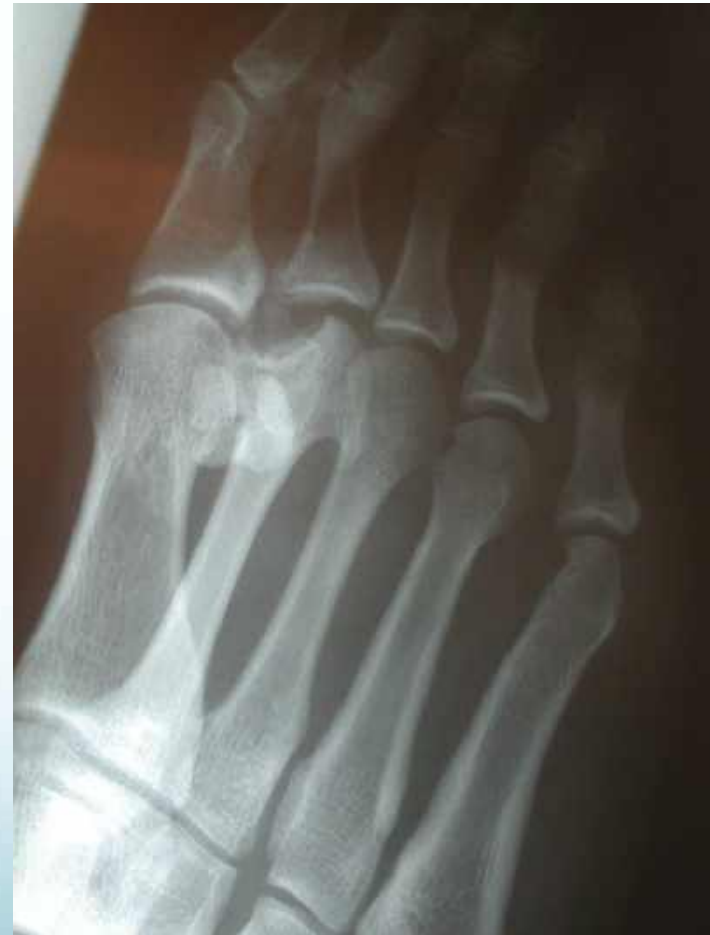
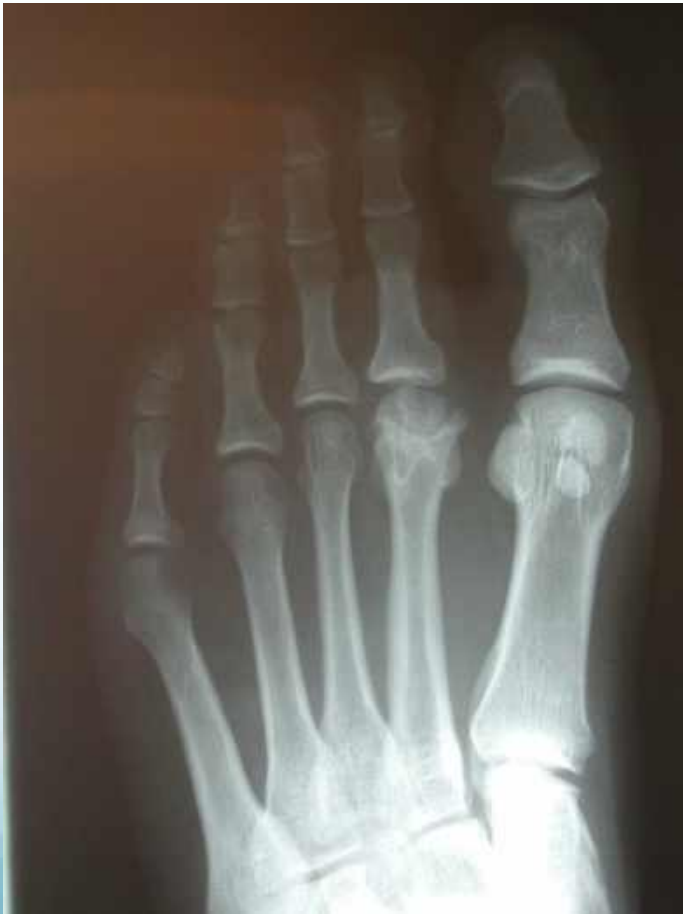
Wedge Resection with Reconstruction



Osteochondrosis

(Softening of bone)



Osteochondrosis

- Vascular change in a bone leading to deformity
- Pain and stiffness base of 2nd or 3rd toe
- Younger age groups, Osteoarthritis older patients
- Plain x-rays
- Early treatment = rest, immobilisation, aircast
- Later treatment = reconstructive surgery

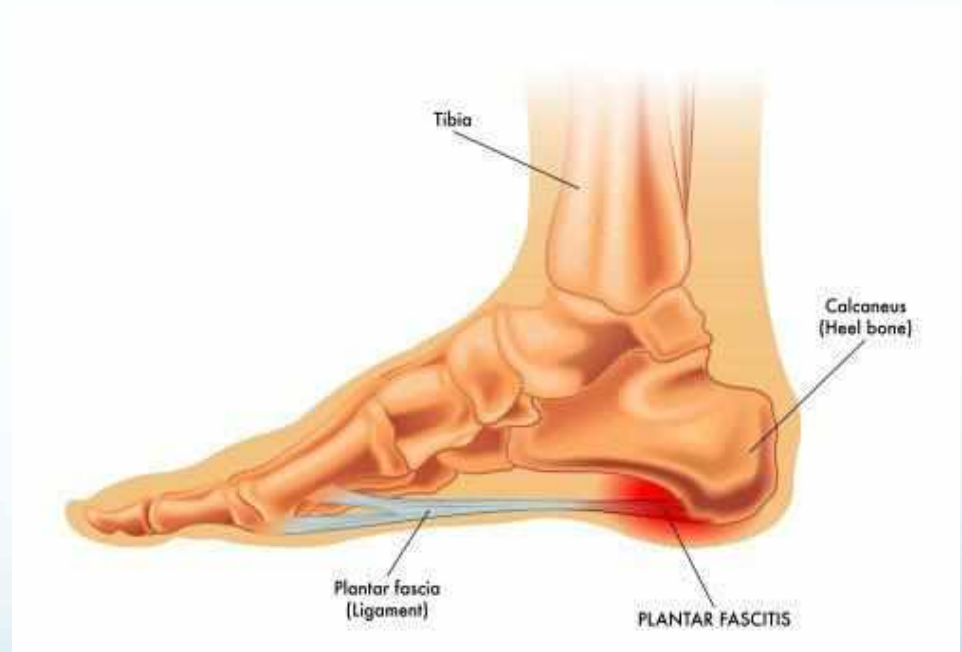Heel Pain

- Plantar Fasciitis / Mechanical dysfunction
- Spinal pathology / sciatica
- Tarsal Tunnel syndrome / Nerve entrapment
- Tendonitis / Tenosynovitis
- Fracture
- Sever's
- Osteoarthritis

Plantar Fasciitis

Policeman's Heel

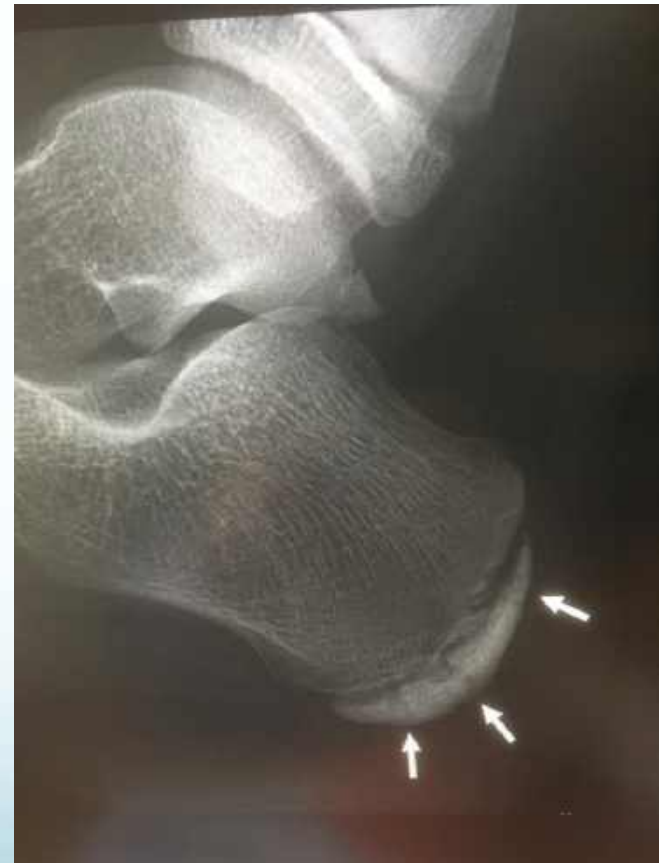- Pain on getting up
- Under the center heel
- Female 40 to 60yrs
- Ice, Stretch, Insoles, heel lift, supportive shoe, pain killers
- Shockwave
- Hoka, Sketchers
- Injection (rare !)
- Surgery (never !!)

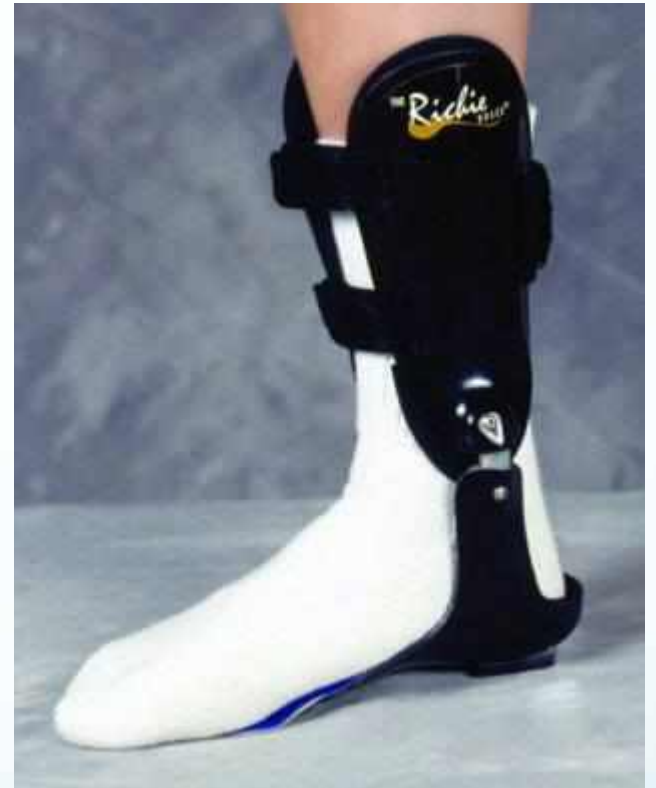
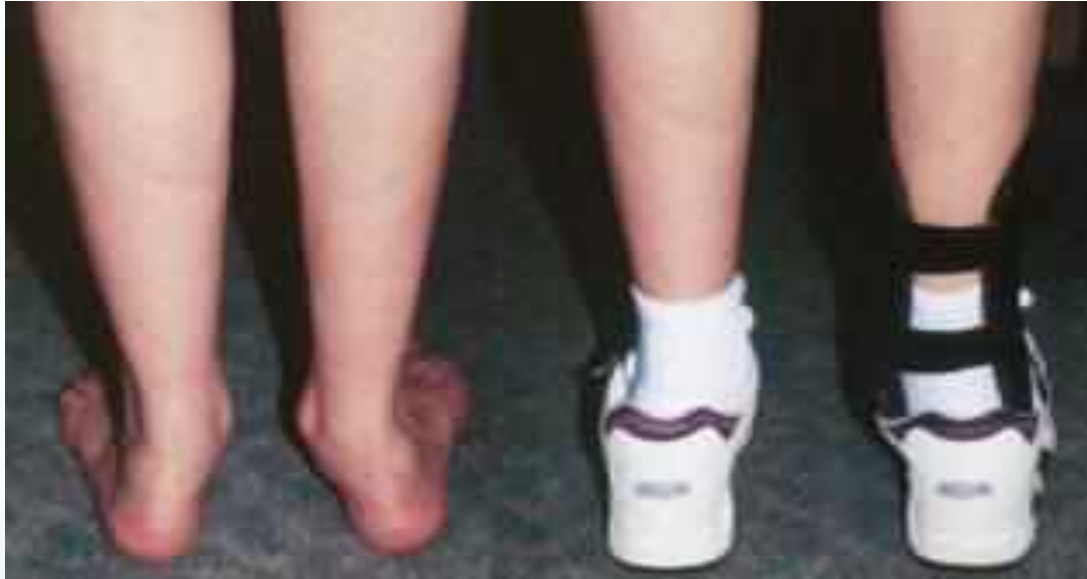
Sever's Disease

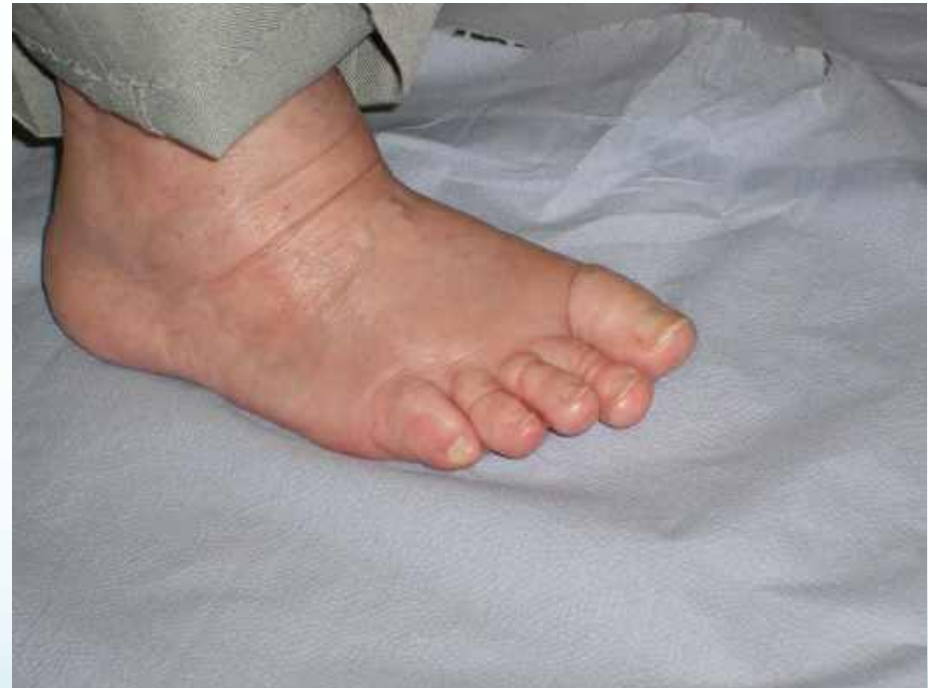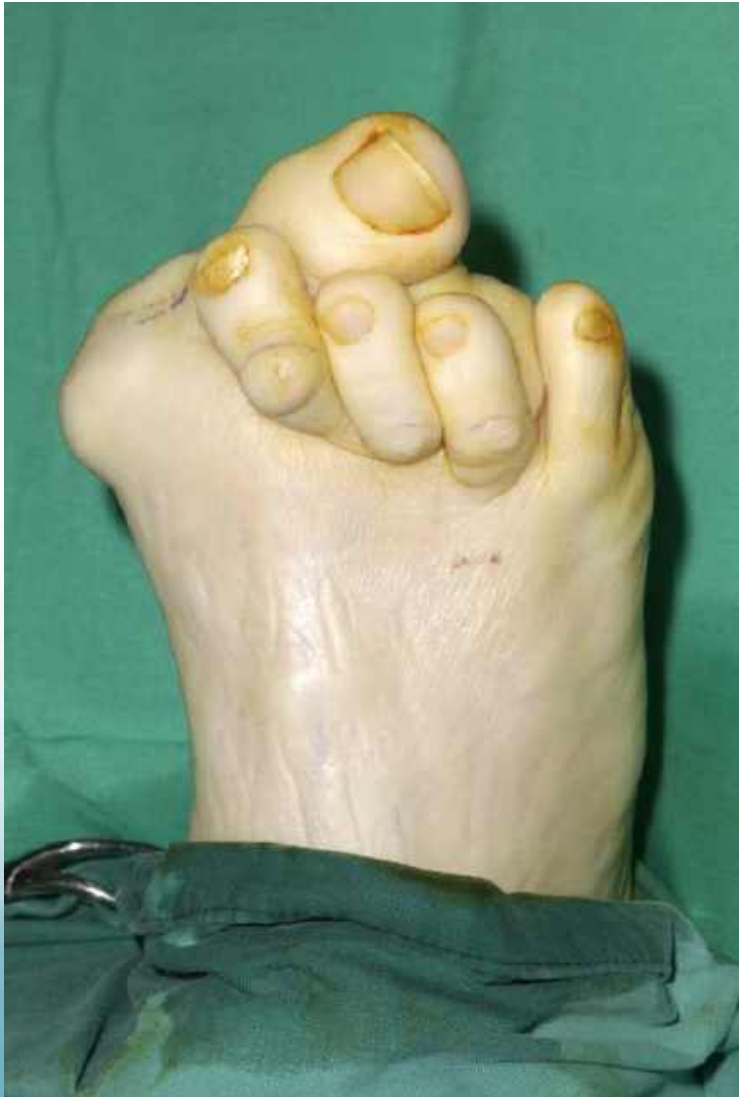Calcaneal apophysitis

- 9 to 12 yr olds
- **Excess Sport +++**
- Pain after / with activity
- **Tight Achilles / High Arch**
- **Rest** / Ice/ NSAID's
- Heel Raise / Orthoses
- Aircast





Before and After



Thank You

