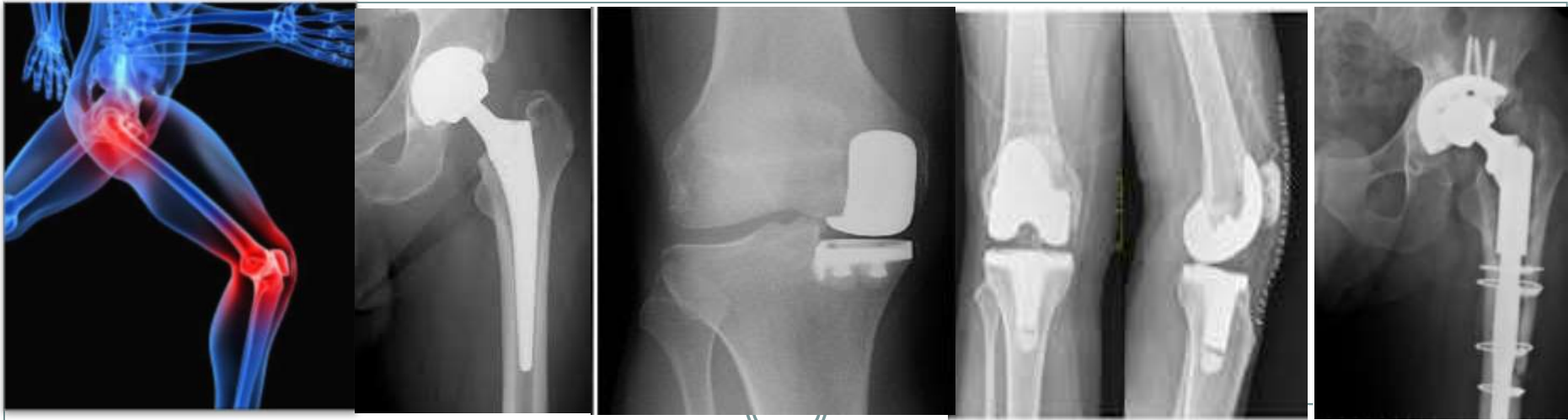

Mr PRAVEEN PANOSE

**MBBS, DNB Orth, FRCS Tr&Orth, MS Orth
Consultant Hip & Knee Surgeon**

Email: hipandkneespecialist@gmail.com

Tel: 01883337484 / 01293 785511

Practice Locations



- NHS Base
SASH – East Surrey Hospital
- Private Practice
Spire Gatwick Park &
Ramsay North Downs hospitals
- Orthopaedic Clinical Director at SASH

Areas of Specialisation



- Hips
 - Replacement
 - Mini Incision Hip replacement
 - Hip Arthroscopy (**Keyhole** surgery of the Hip)
 - Revision Hip replacement
 - Sports Injuries
- Knees
 - Replacement
 - Partial Knee Replacement
 - Arthroscopy (**Keyhole** Surgery)
 - Revision Knee replacement
 - Sports injuries
- Trauma
 - Routine and Complex limb fractures

Hip Replacements – NJR data



P Panose

- 1000+ in 10 years
- Infection- 0.2%
- Dislocation – 0.3%
- mortality rates in line with national average

National average

- 500
- 1.2%
- 1.5%

Causes of Hip Pain?

Arthritis

- Juvenile rheumatoid arthritis
- **Osteoarthritis**
- Psoriatic arthritis
- Rheumatoid arthritis
- **Septic arthritis**

Injuries

- **Bursitis**
- Dislocation
- **Hip fracture**
- **Hip labral tear**
- Inguinal hernia
- **Sprains and strains**
- **Tendinitis**
- **Avulsion injuries**

Pinched nerves

- Herniated disc
- Meralgia paresthetica
- Sciatica
- Spinal stenosis
- Piriformis syndrome

Cancer

- **Metastases**
- Bone cancer
- Leukemia

Other problems

- **Avascular necrosis**
- Legg-Calve-Perthes disease
- Osteomyelitis
- Osteoporosis
- Rickets
- Synovitis
- Sacroiliitis
- Psoas Abscess
- **Sports hernia**
- **Vascular disease**



The Short List!

- Avulsions
- Muscle strains
- Ligament sprains
- **Stress fractures**
- **Osteoarthritis - Primary/Secondary**
- Snapping hip
- Trochanteric pain syndromes
- **Avascular necrosis**
- **Femoro acetabular impingement/
Labral lesions**
- Bone bruising/chondral injuries

You call
this a
short
list?!



Diagnosis



- History {patient's story}
- Examination
- Tests

Hip History



- Trauma (hyperextension/lateral blow/splits)
- Pain in certain positions (sitting or lying on side) or activities
- May have clicks or snaps or sensation of giving way /instability
- Drug history – steroids/alcohol/bisphosphonates/statins
- Snapping ('dislocating') hips
- Stiffness
- Positional pain



- The individual story is the clinching factor!
- The Story may change!

Hip examination



- Appearance, gait, leg lengths
- Tenderness and its location
- Range of motion
- Impingement (pain with flexion + int rotation)
- Painful muscle insertions and test against resistance
- Demonstrable snap (Flex-ER to Ext-IR)
- Special tests
- Spinal examination incl. Neurology

Last but not least . . .



- The unexpected bouncers

KNEE PAIN!!!
SPINE {BACK}!

Osteoarthritis



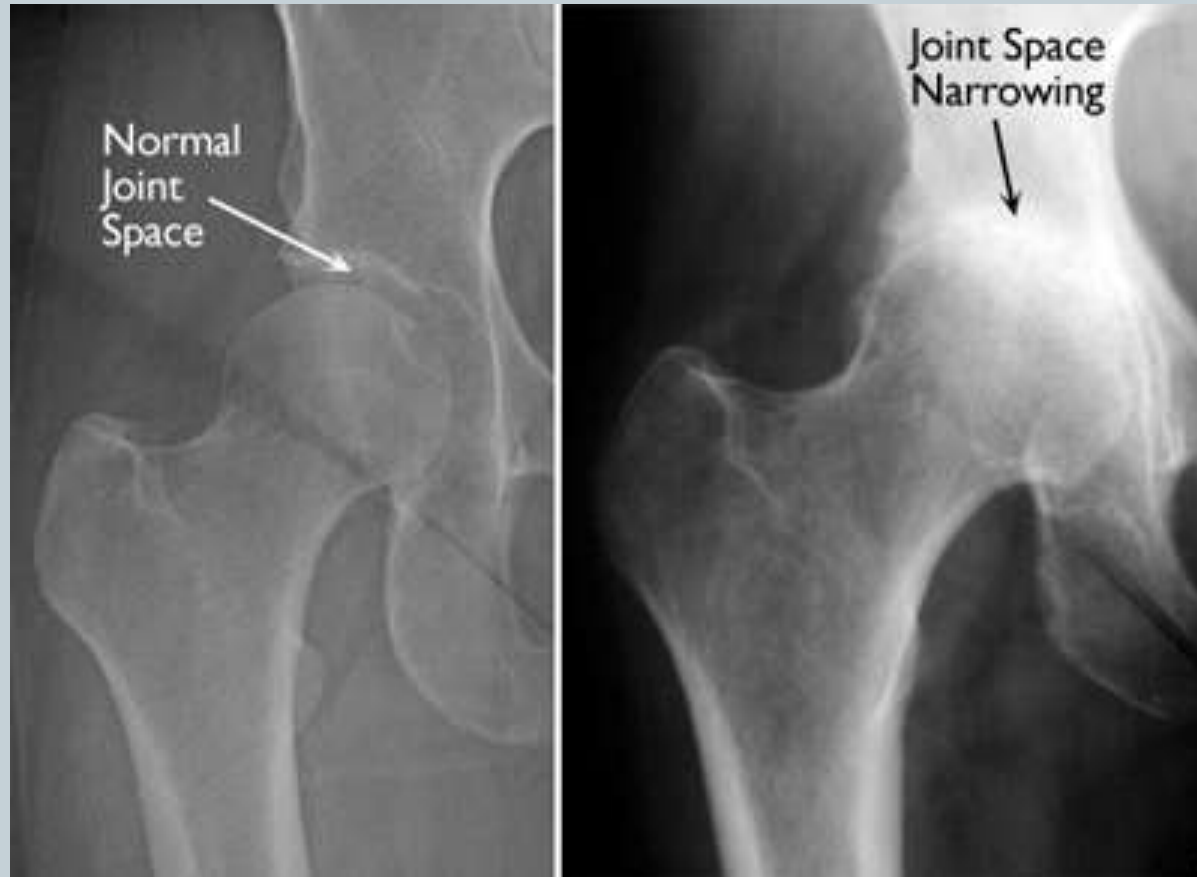
- Hip/buttock/groin/thigh...Knee! Pain
- Stiffness
- Age/genes/usage/injury/body wt
- Xray/...rarely further tests

Real world Hip Examination (2-3 minutes)



- Watch the gait –stiffness/pain/limp
- Where is the pain?
 - Groin/buttock /thigh/knee
 - Lateral hip pain
 - Muscle attachments
- Palpate the muscle attachment /bursal areas especially lateral (or relevant areas from history)
- Supine on couch – hip flexion and rotation
- Ask about back and knee pain
- Check distal pulses and sensation---Done!!

Arthritic Hip

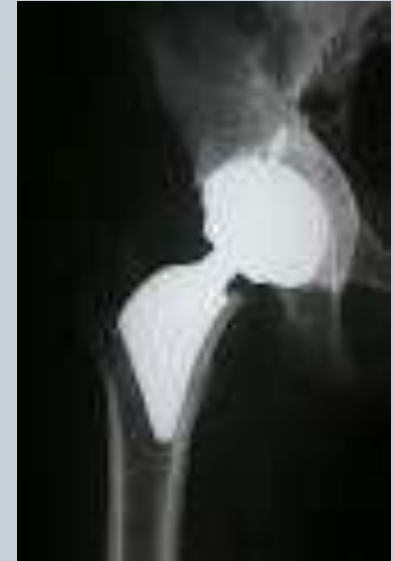
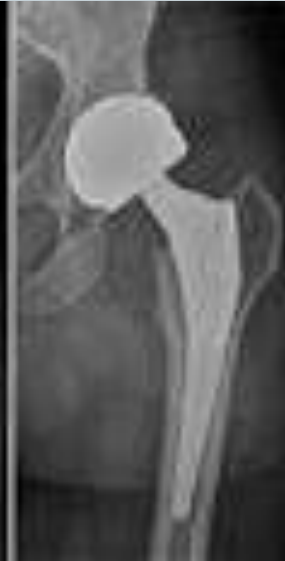
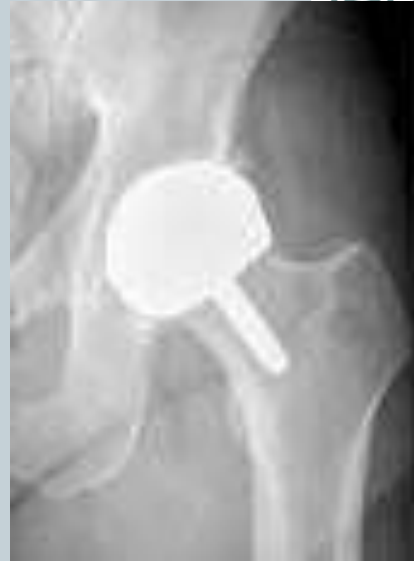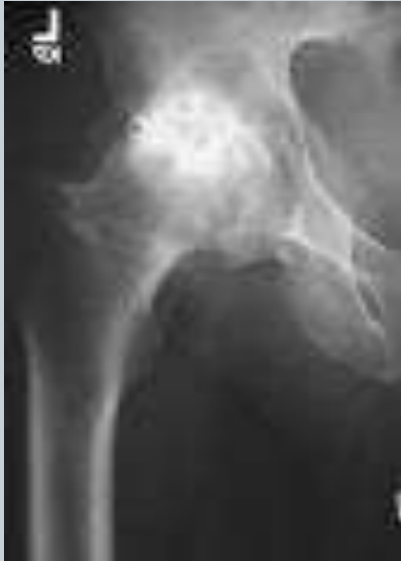Treatments



- Activity modification/ Analgesics and NSAIDs / weight loss
- Physiotherapy
- Steroid injection
- Platelet rich plasma injections
- Stem cell therapy
- Hip Resurfacing
- Hip replacement
- Revision hip replacements

Surgery for arthritic hip



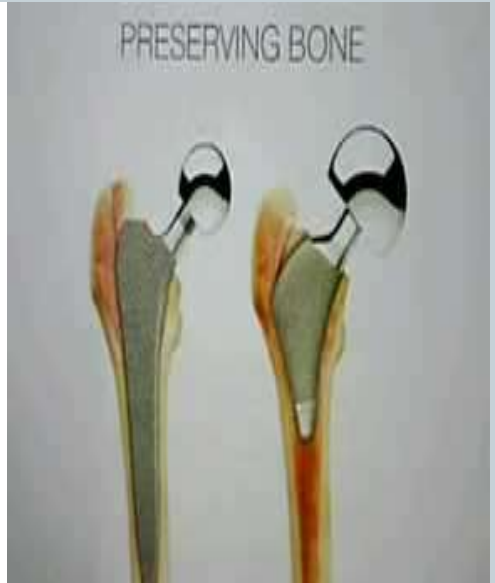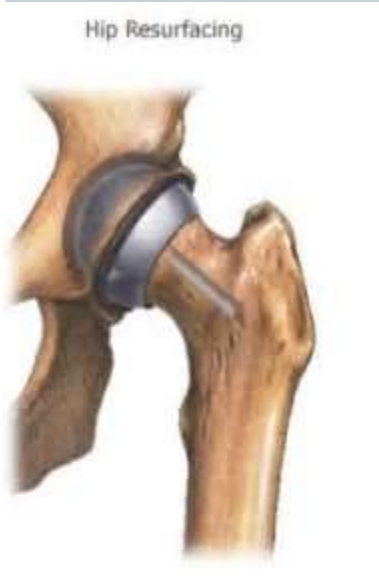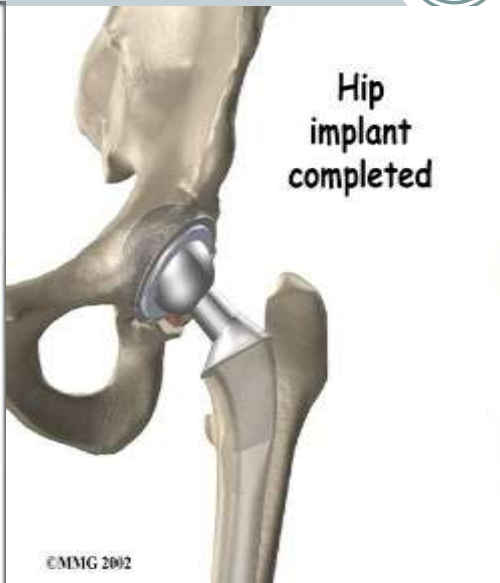
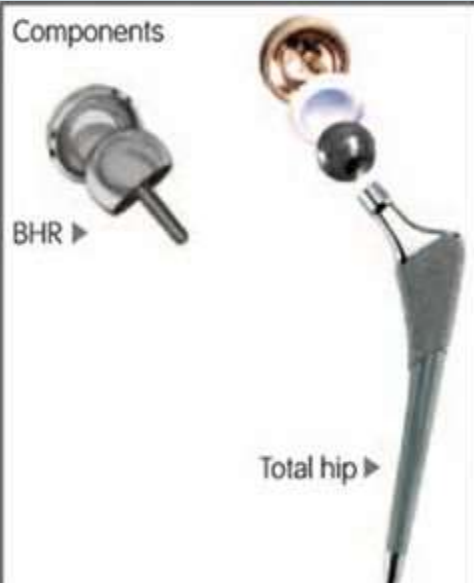The problem?



- NHS
- CCGs
- GP Practices
- Patients!



Hip replacements

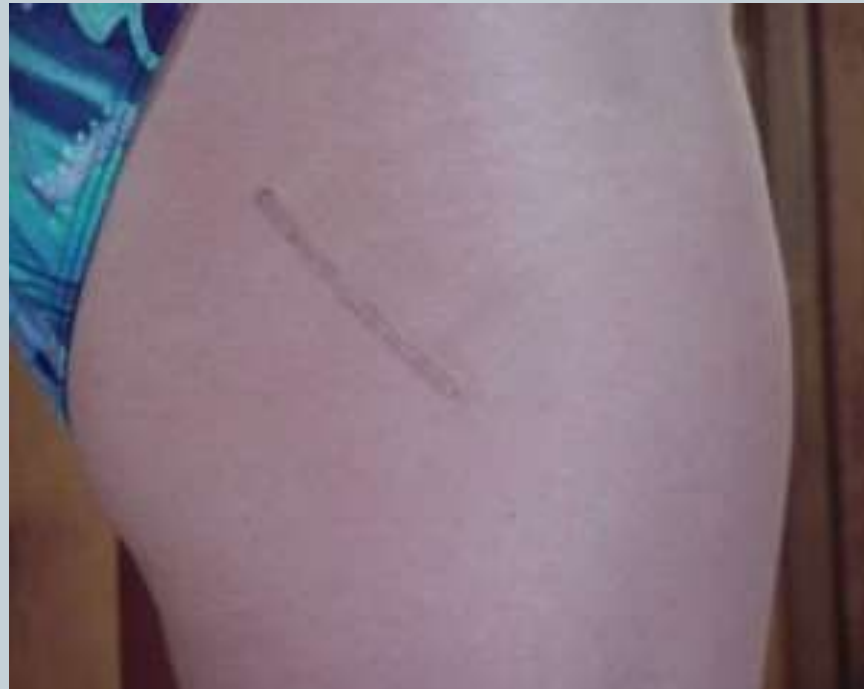

Hip replacements



- Tailored to individual needs
- Can be minimally invasive
- 95% satisfaction rate

Minimally Invasive hip scar



Hip Arthroscopy



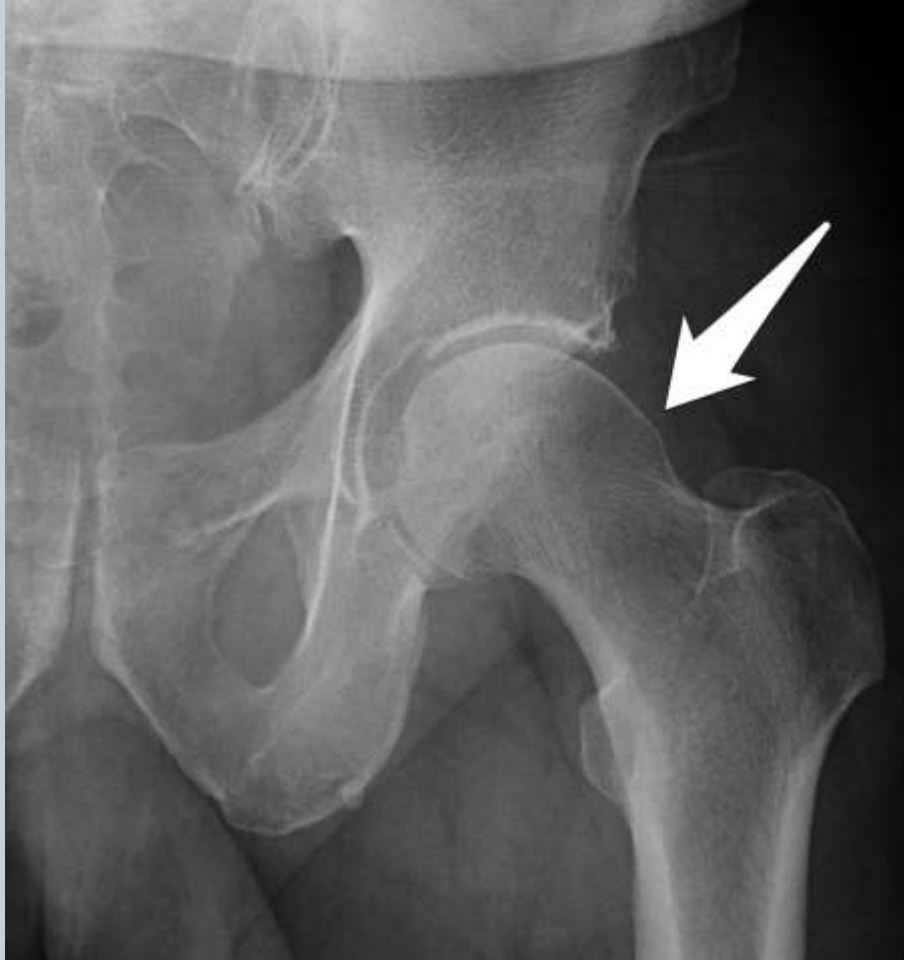- Labral debridement / repair
- Femoroacetabular Impingement surgery
- Loose body removal
- Cartilage repair – chondroplasty / microfracture
- ITB Release/ Snapping psoas division
- Septic Arthritis – washout
- Post THR painful hip

FAI- Femoro-Acetabular Impingement

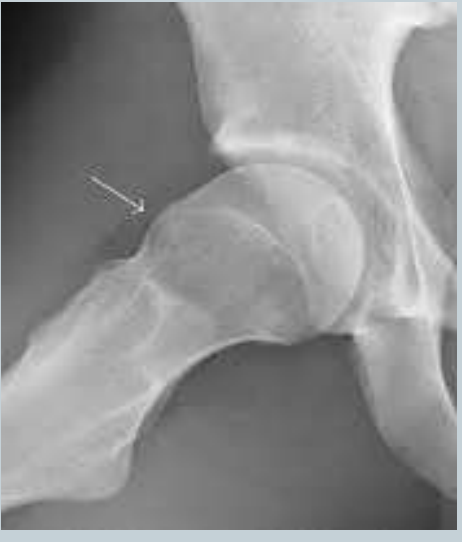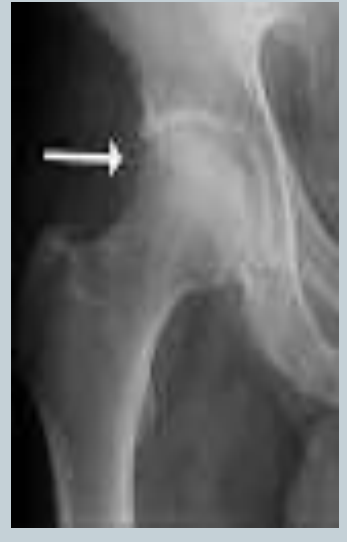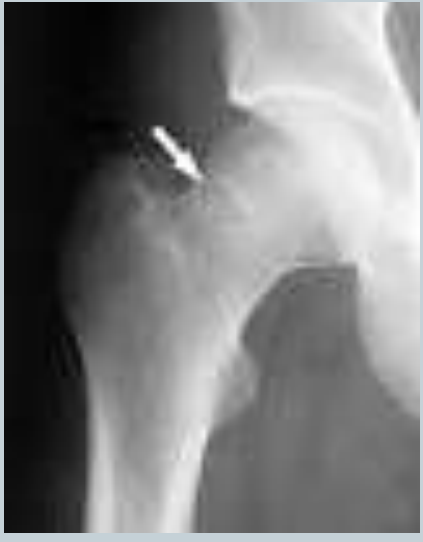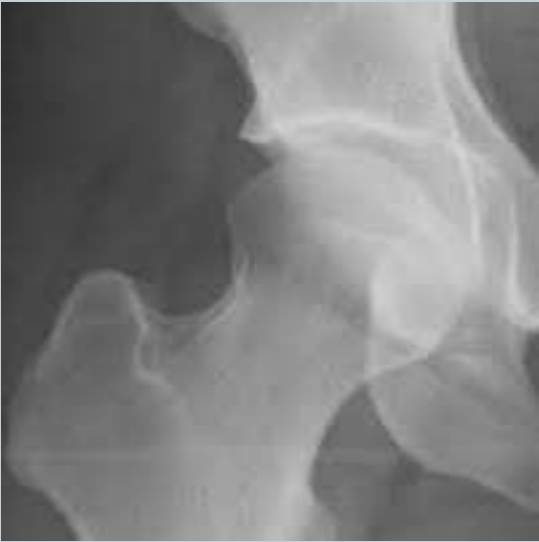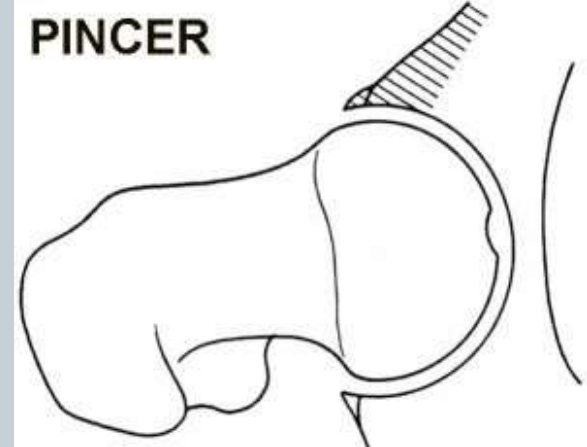
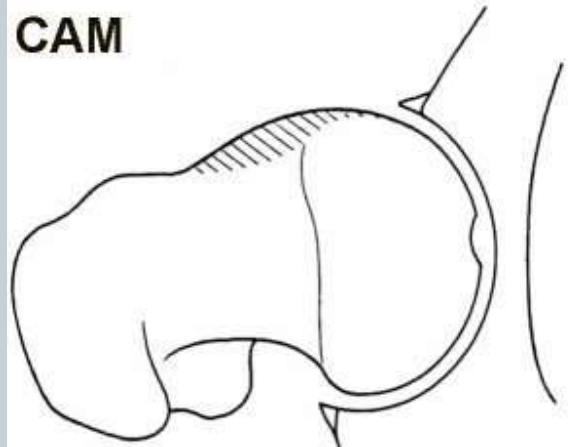
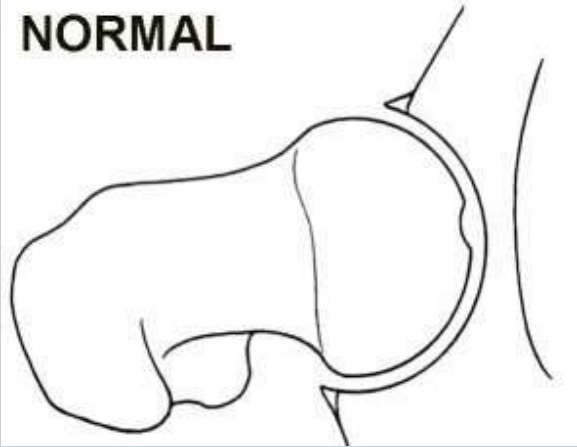


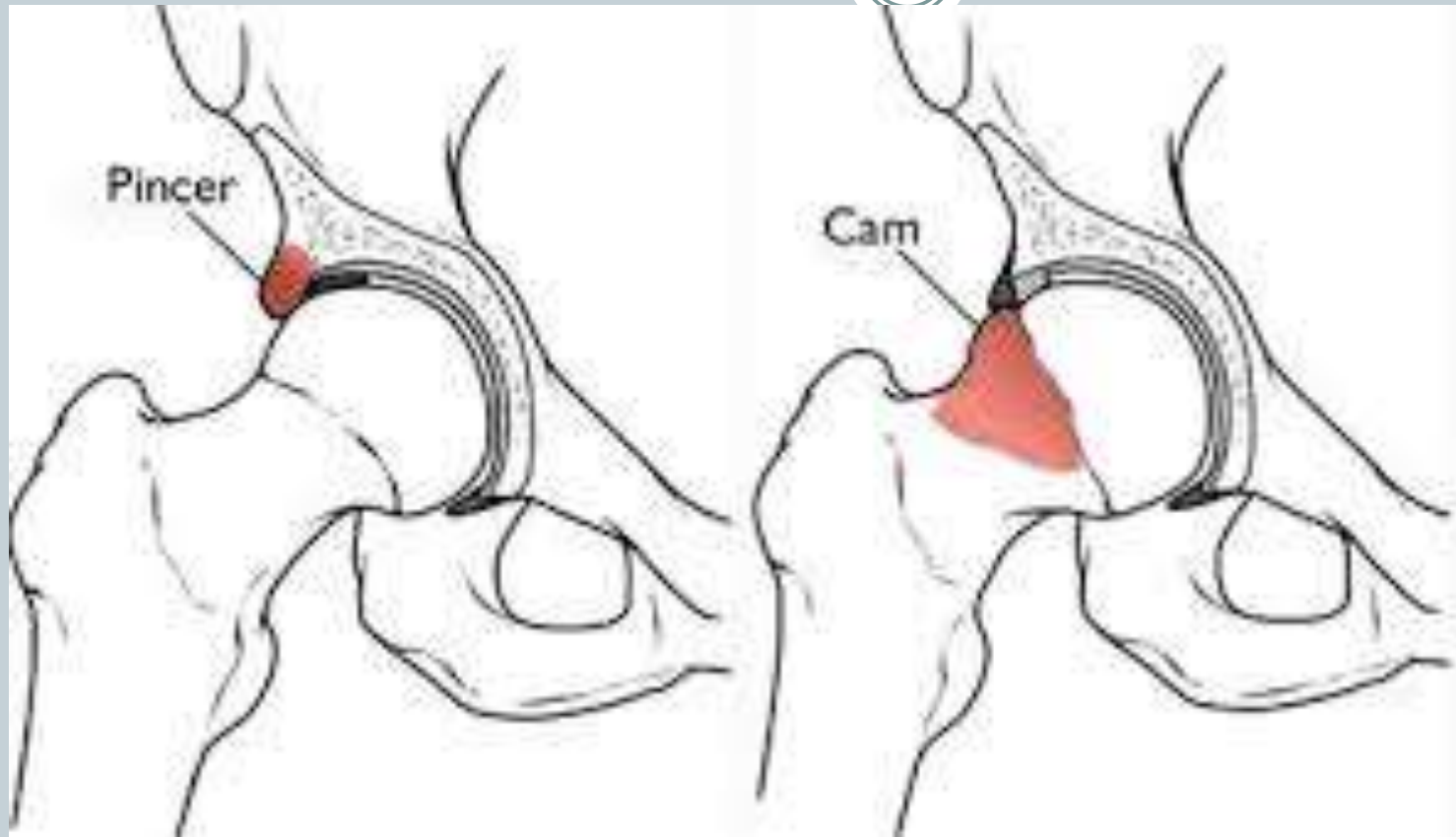
- Groin pain –poorly localised
- Related to activity/sport
- Clicking hip- labral tears
- Younger person





Femoroacetabular impingement

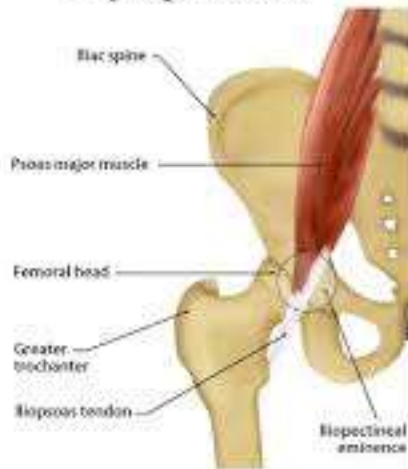



Snapping/Clicking or Popping hip



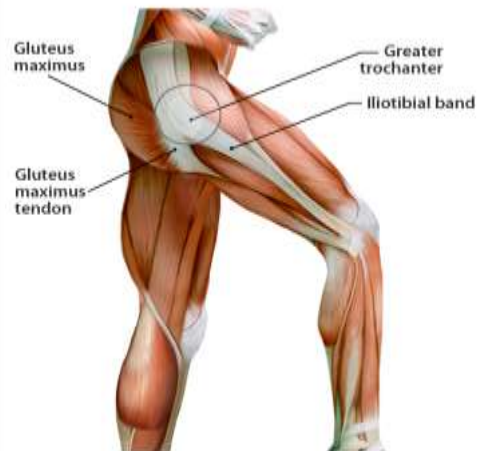Internal Snapping Hip Syndrome



Internal snapping hip syndrome occurs when the iliopectineal tendon catches on the femoral head or iliopectineal eminence during hip flexion.

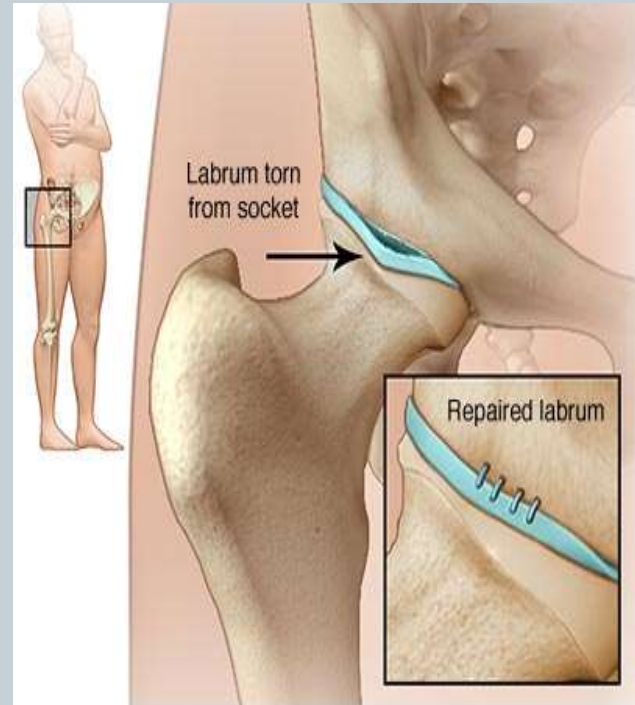
MendMeShop™ © 2011

External Snapping Hip Syndrome



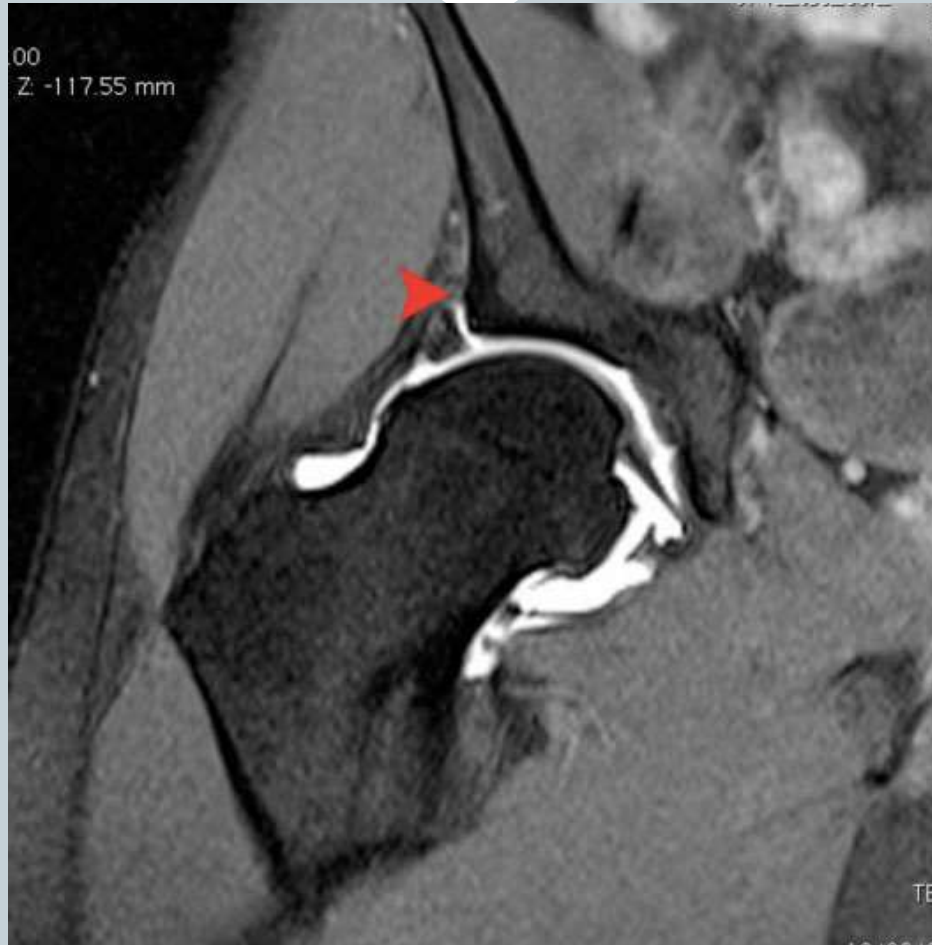External snapping hip syndrome occurs when the gluteus maximus tendon or iliotibial band catch on the greater trochanter during flexion.

MendMeShop™ © 2011

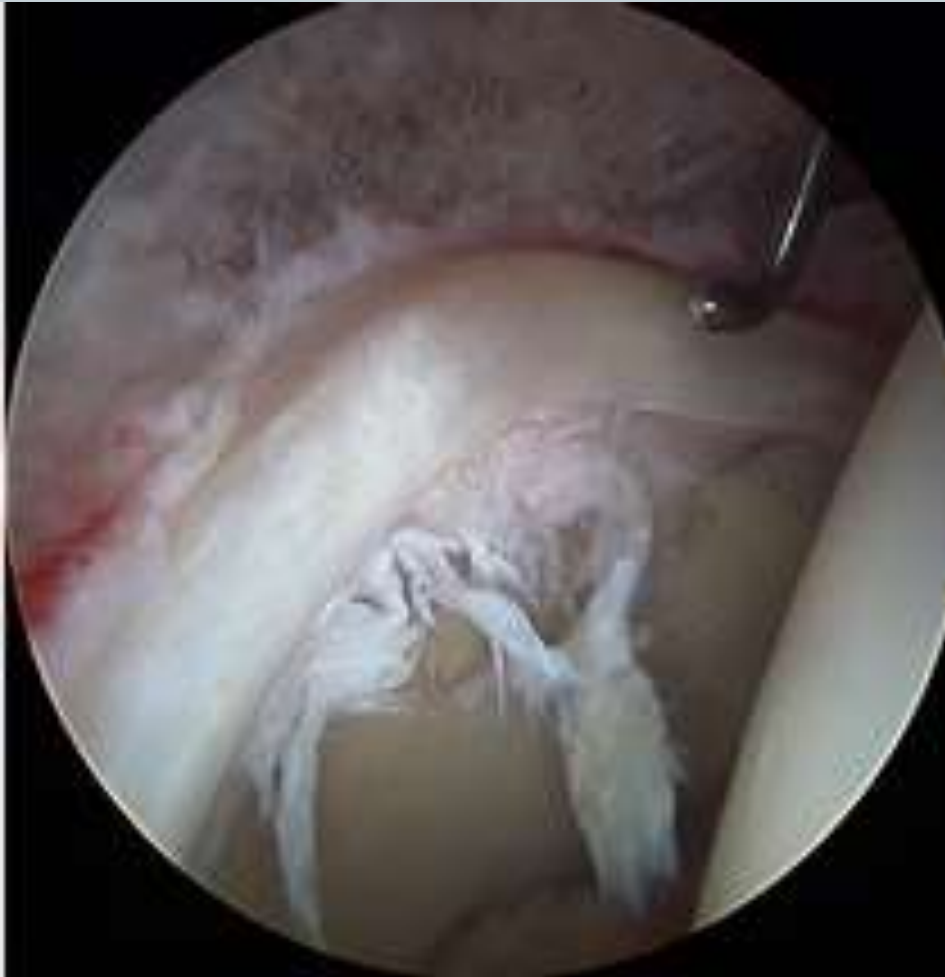

© MAYO FOUNDATION FOR MEDICAL EDUCATION AND RESEARCH. ALL RIGHTS RESERVED.

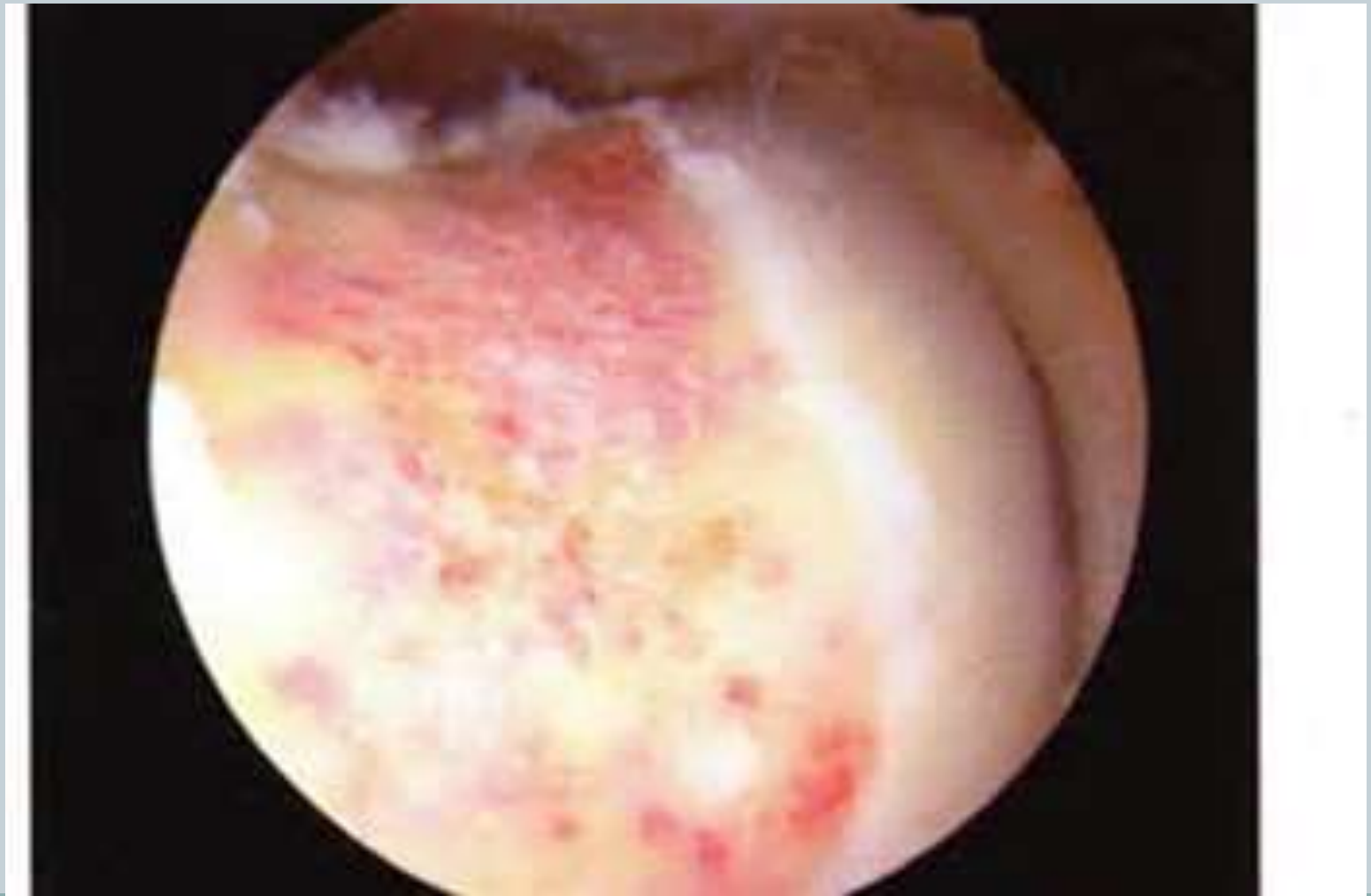MRI- Labral tear



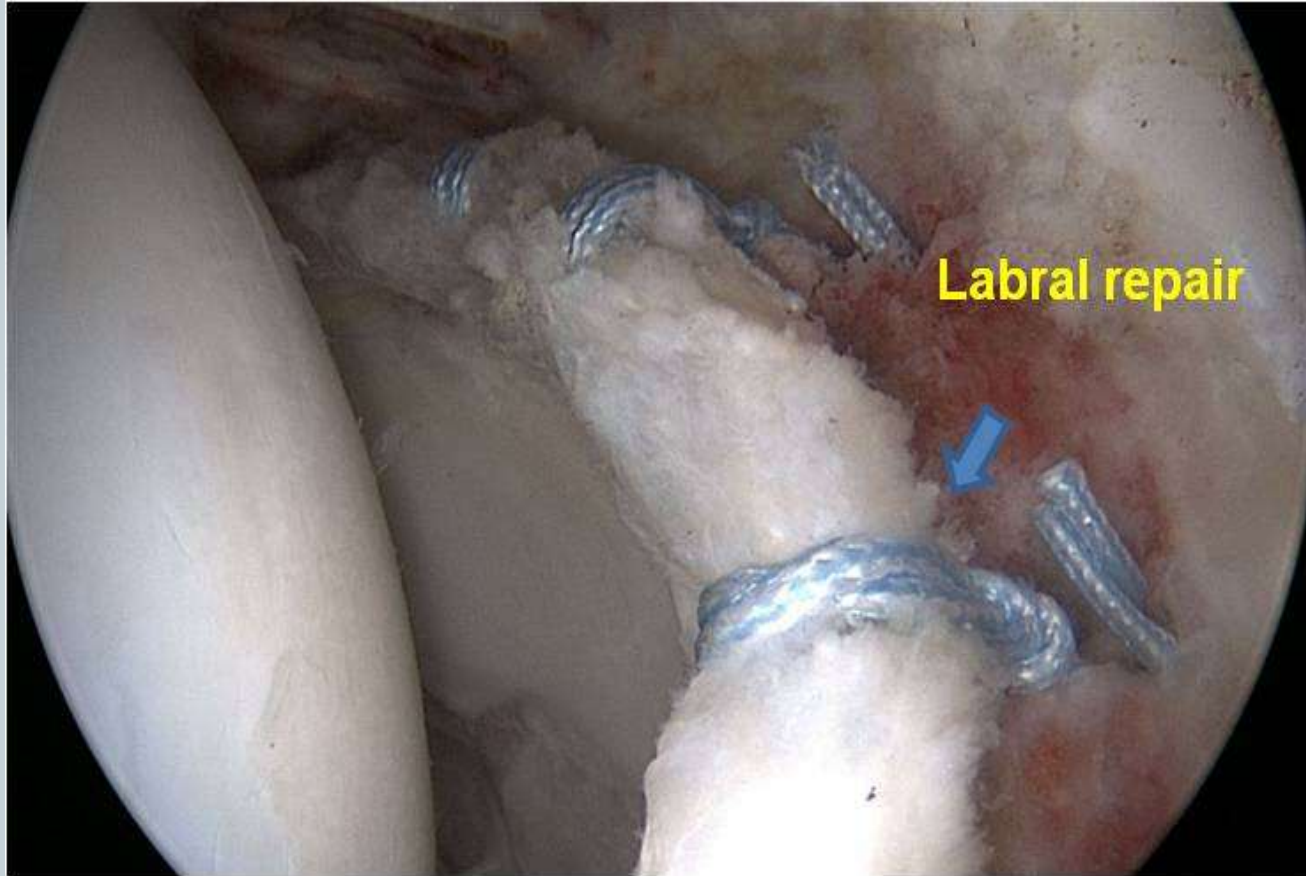
Labral tear



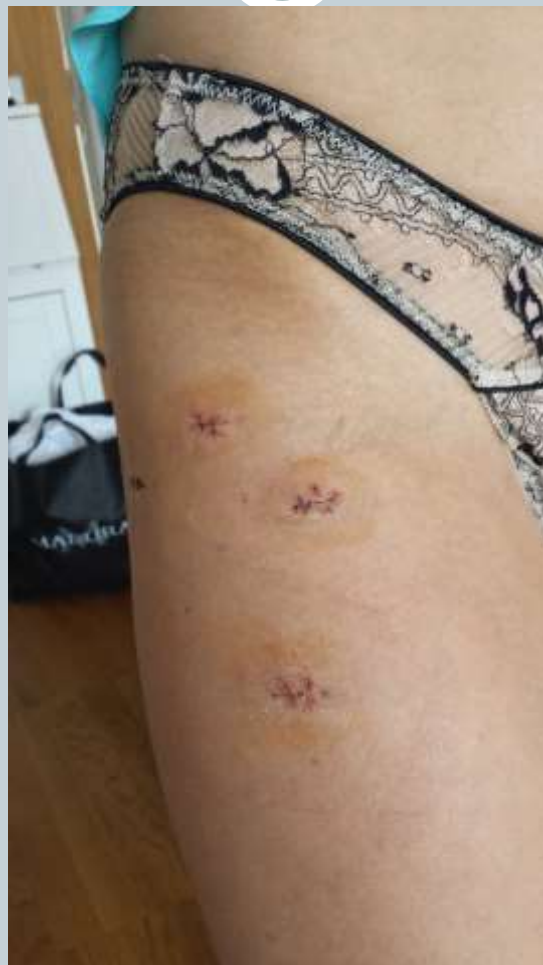Excised Cam



Labral repair



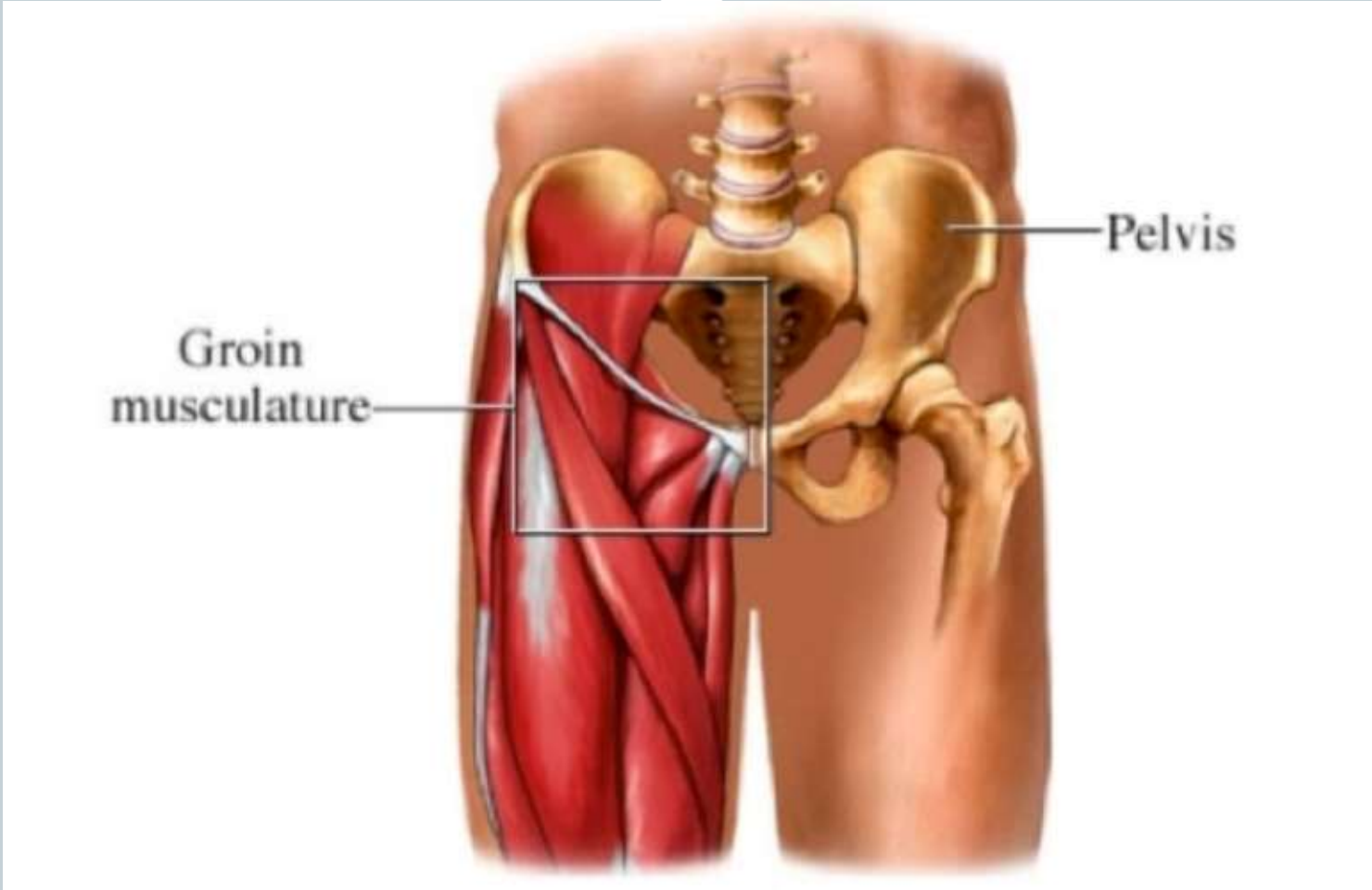
Keyhole surgery of the hip



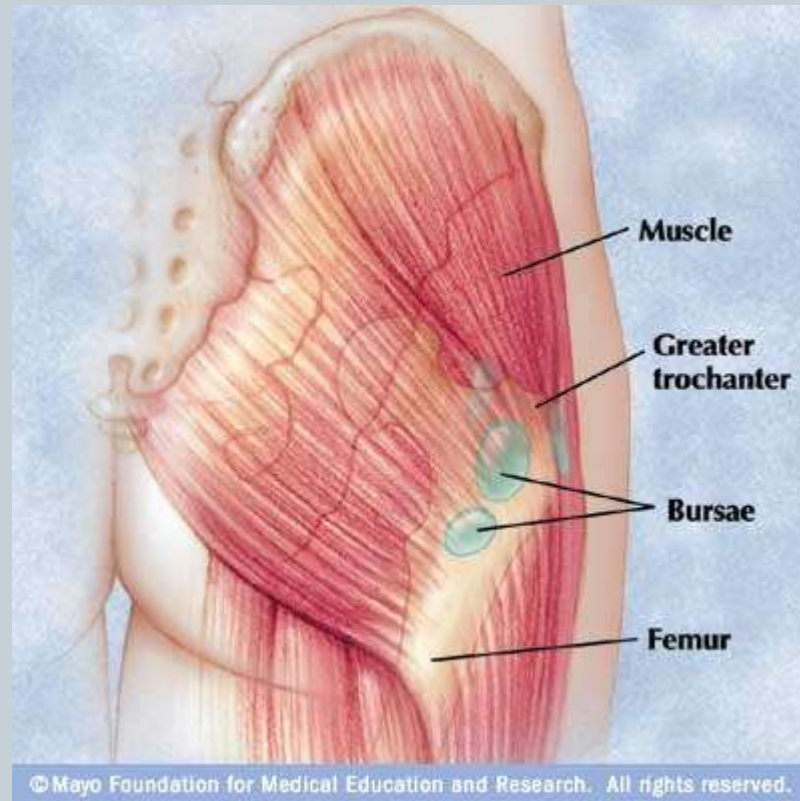
Rehabilitation



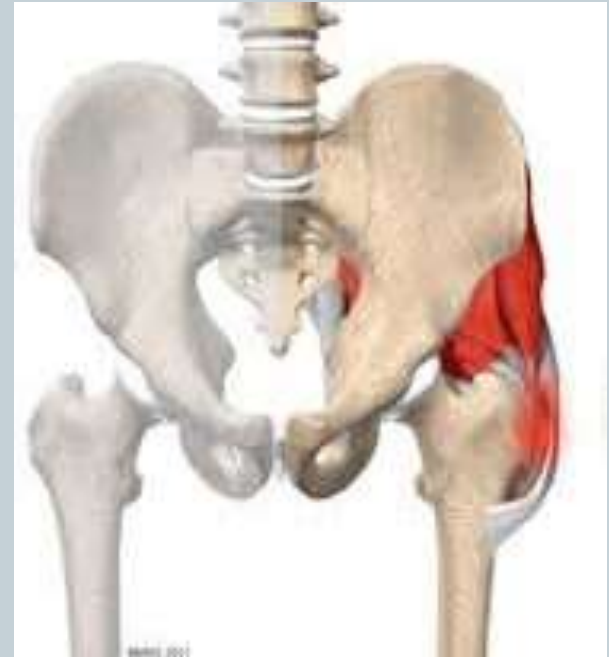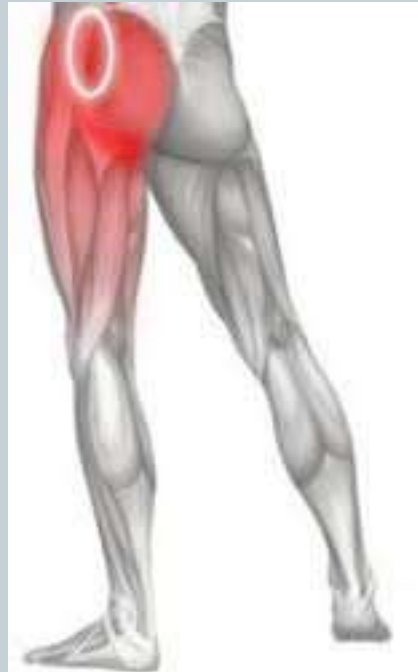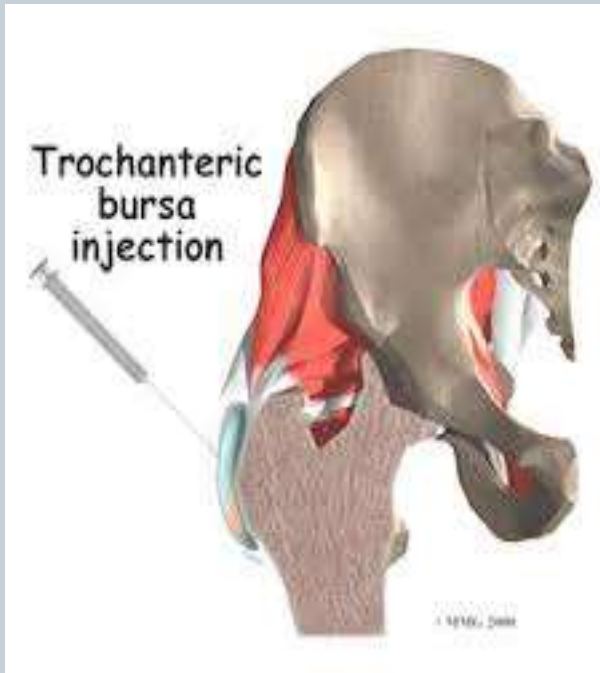
- Graded rehab in stages
- Can usually mobilise ASAP
- Can take months to return to sport



Lateral hip pain



Lateral Hip Pain



Snapping hip



Iliotibial band sliding over the greater trochanter

Not the 'hip popping out'

(also iliopsoas/rectus/hamstrings)

Diagnosis & Reassurance

Steroid Injection

Young sporting injury



Specific history

Anatomic location

Avulsion fractures

X-ray

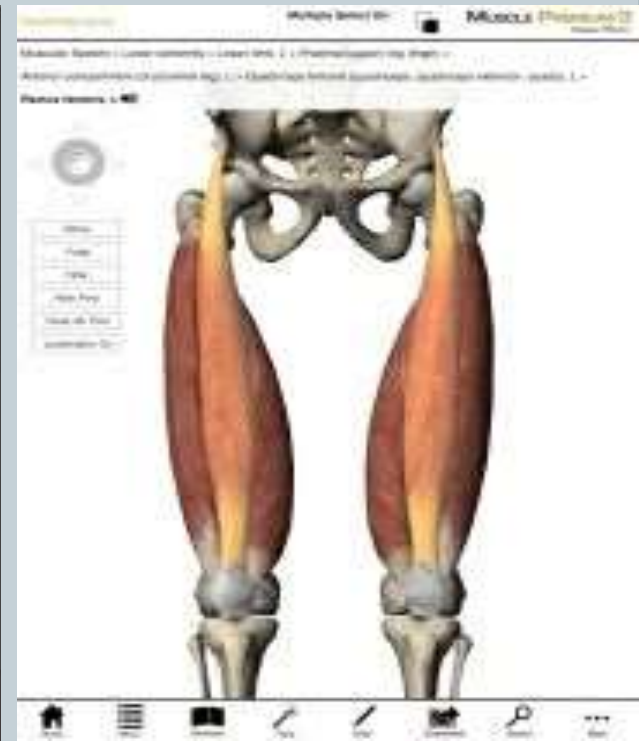
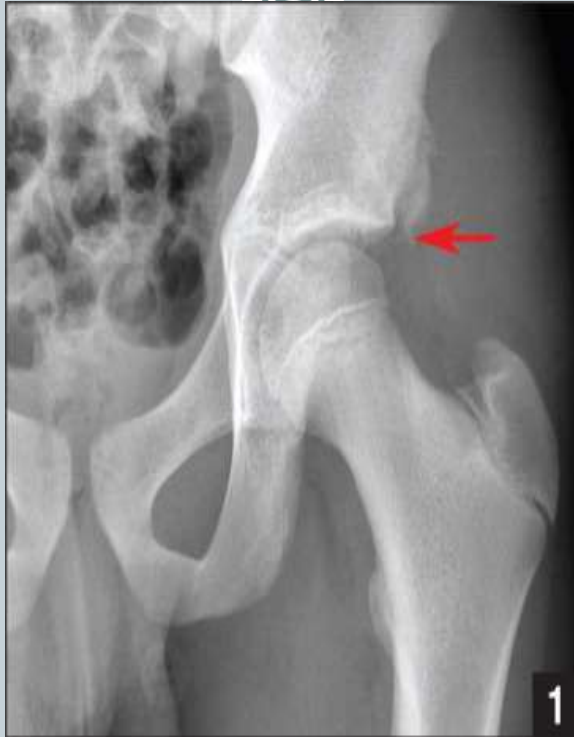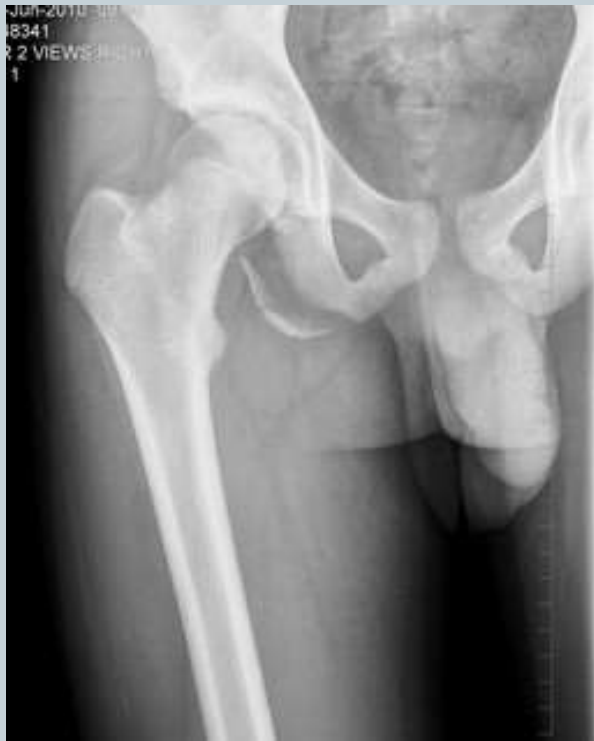Muscle strain/Tendonitis by location and local tenderness

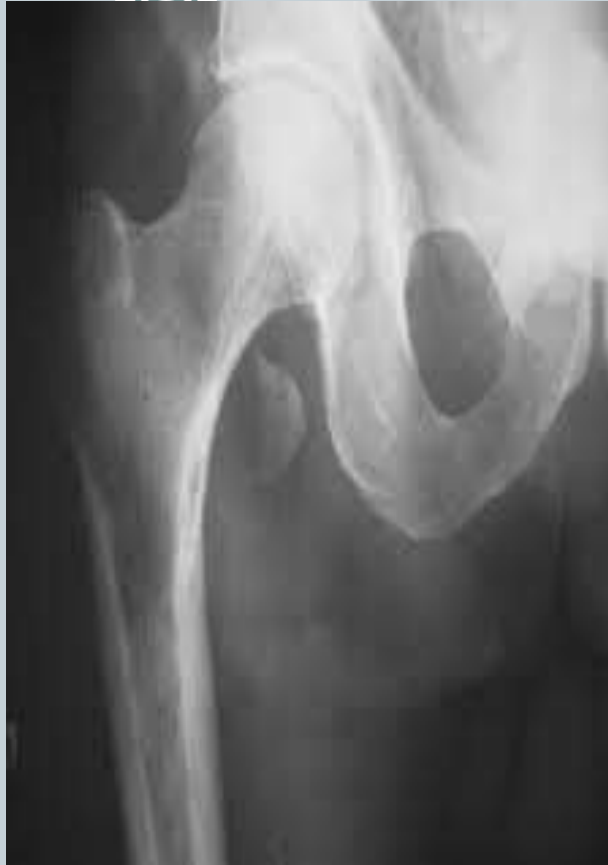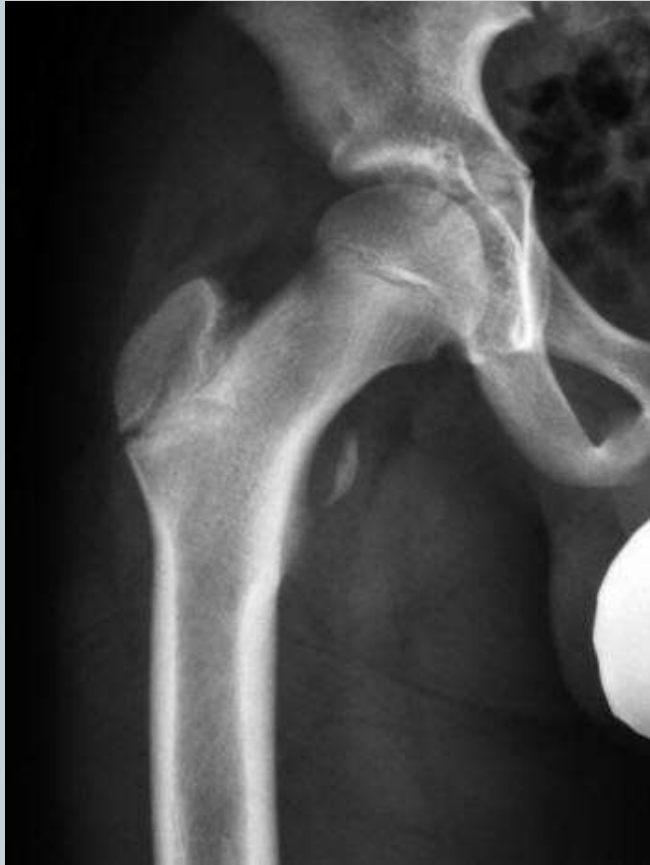Hamstrings/Adductors/Rectus/Iliopsoas

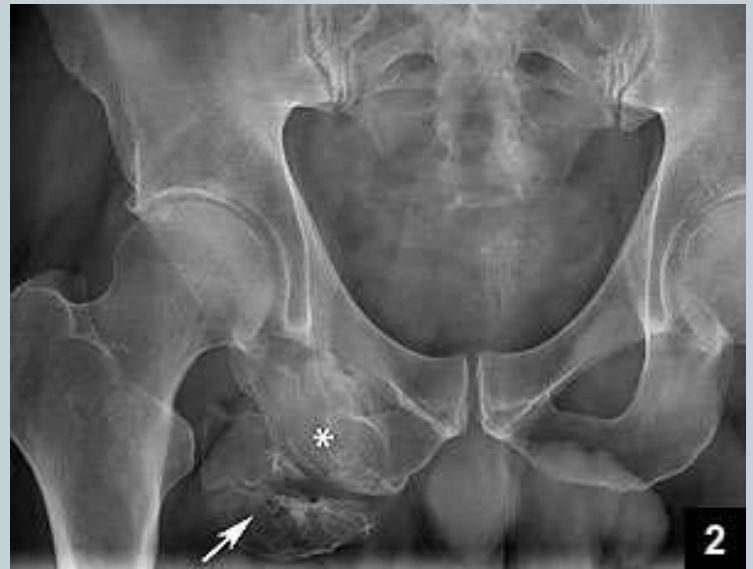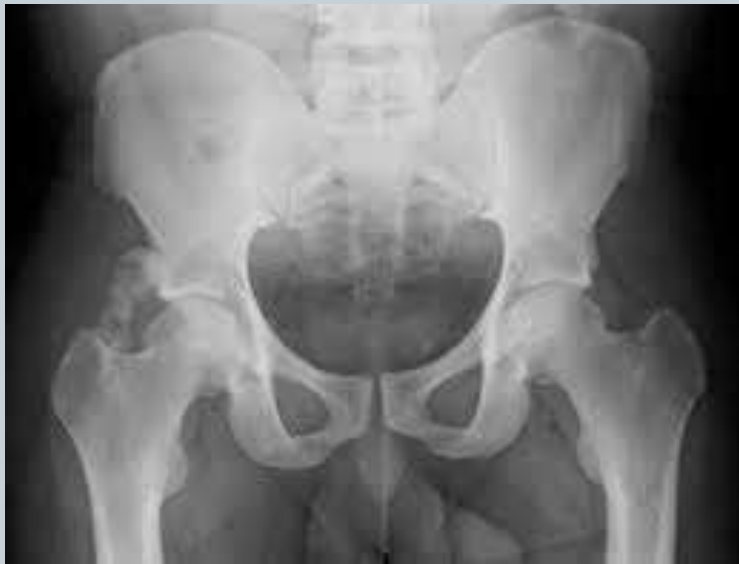Ligament sprains

Anterior pain

M.R.I.







Hip Investigations



- X-rays
- Ultrasound
- MRI or MR-arthrography
- CT
- Bone scan
- Hip Block Injection

Soft Tissue Pathology



Activity modification

Weight loss

Physio

Chiropracty

Injections

Time

Surgery (?Voodoo)

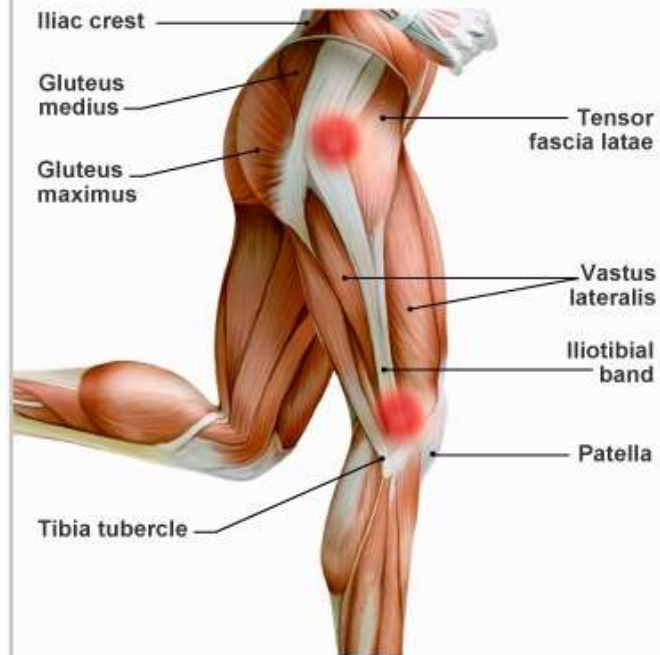
Injections



- Steroid
- PRP- Platelet Rich Plasma



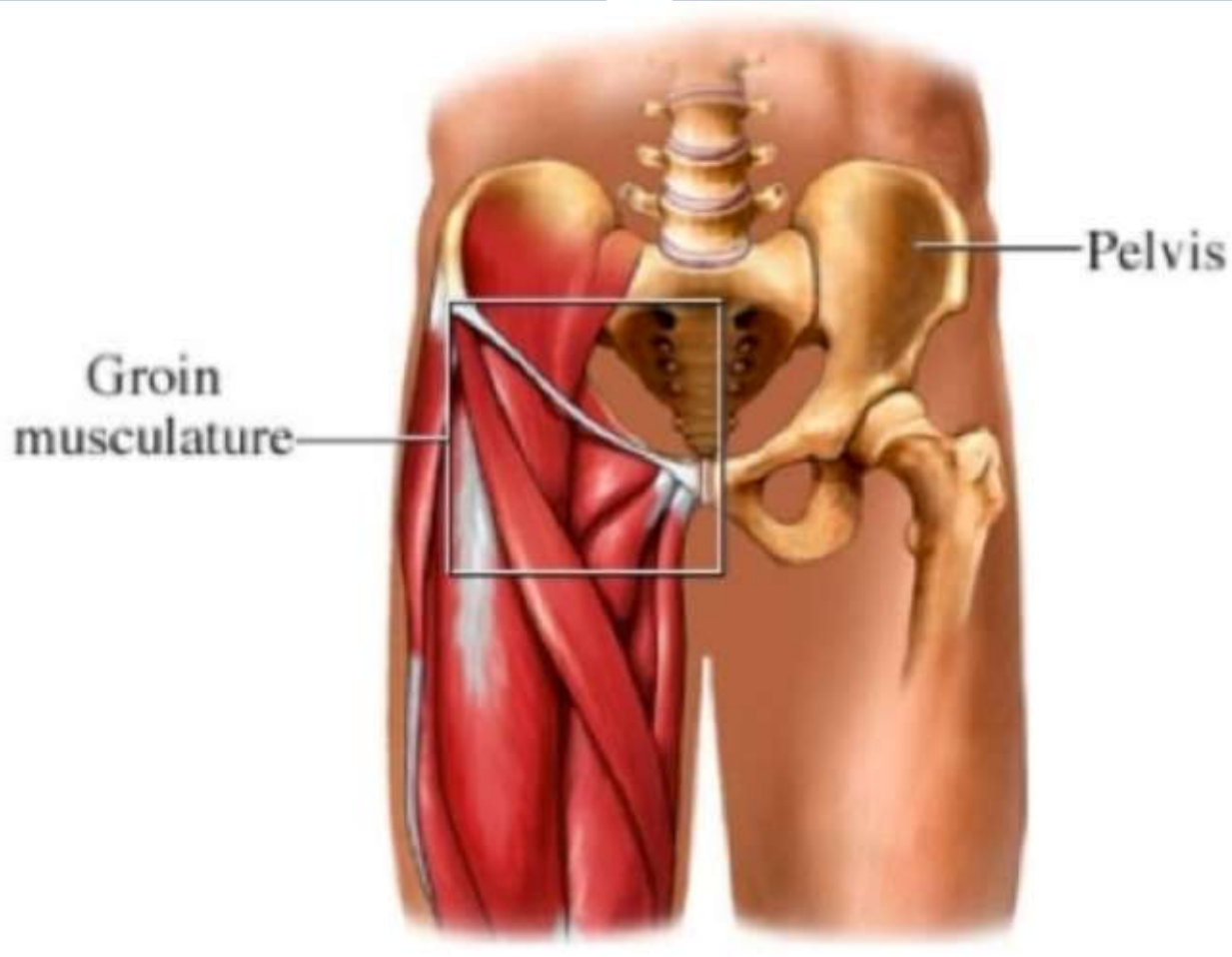
Iliotibial Band Syndrome (ITBS)



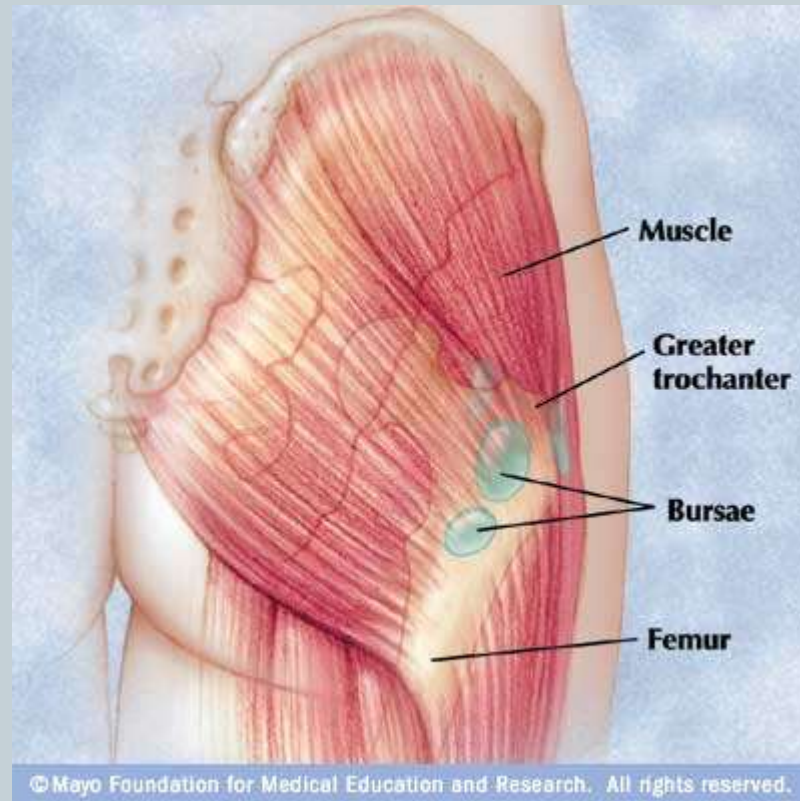
Inflammation of the iliotibial band (ITB) causes outer knee pain and possible pain in the hip.

MendMeShop™ © 2011

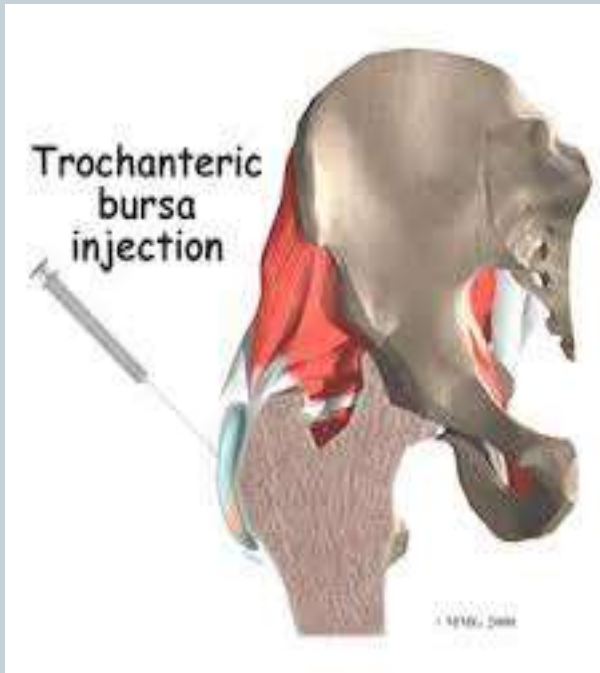
Groin strain/ sports hernia



Lateral hip pain



Lateral Hip Pain

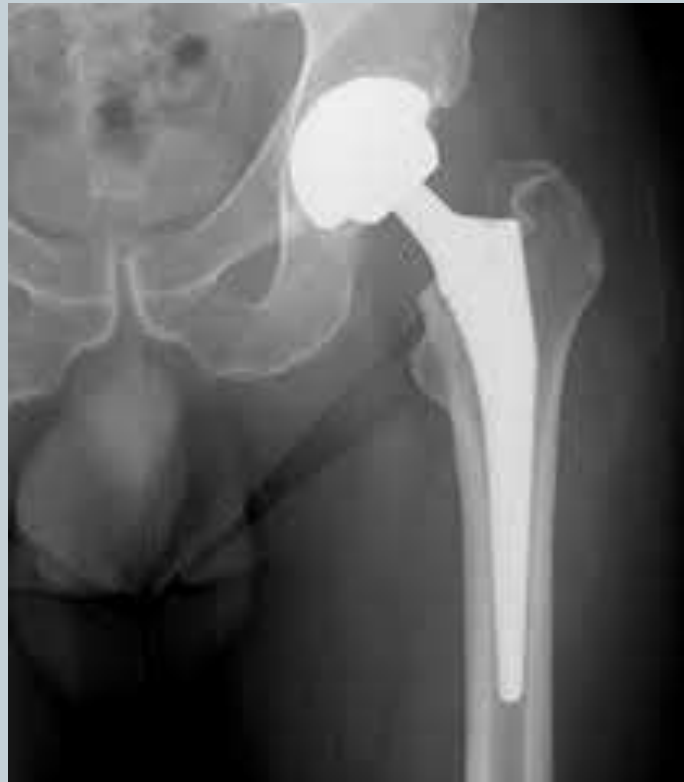

Arthritis



- Painful stiff hip
- Reduced exercise tolerance
- Reduced R.O.M.
- X-ray is mostly diagnostic
- Bone scan/CT
- Therapeutic trial of steroid infiltration

XRAY



Hip Replacement Surgery



- Cemented and uncemented
- Metal on plastic
- Ceramic on plastic
- Ceramic on ceramic
- Minimally invasive surgery
- Muscle sparing
- Hip resurfacing

Rehab



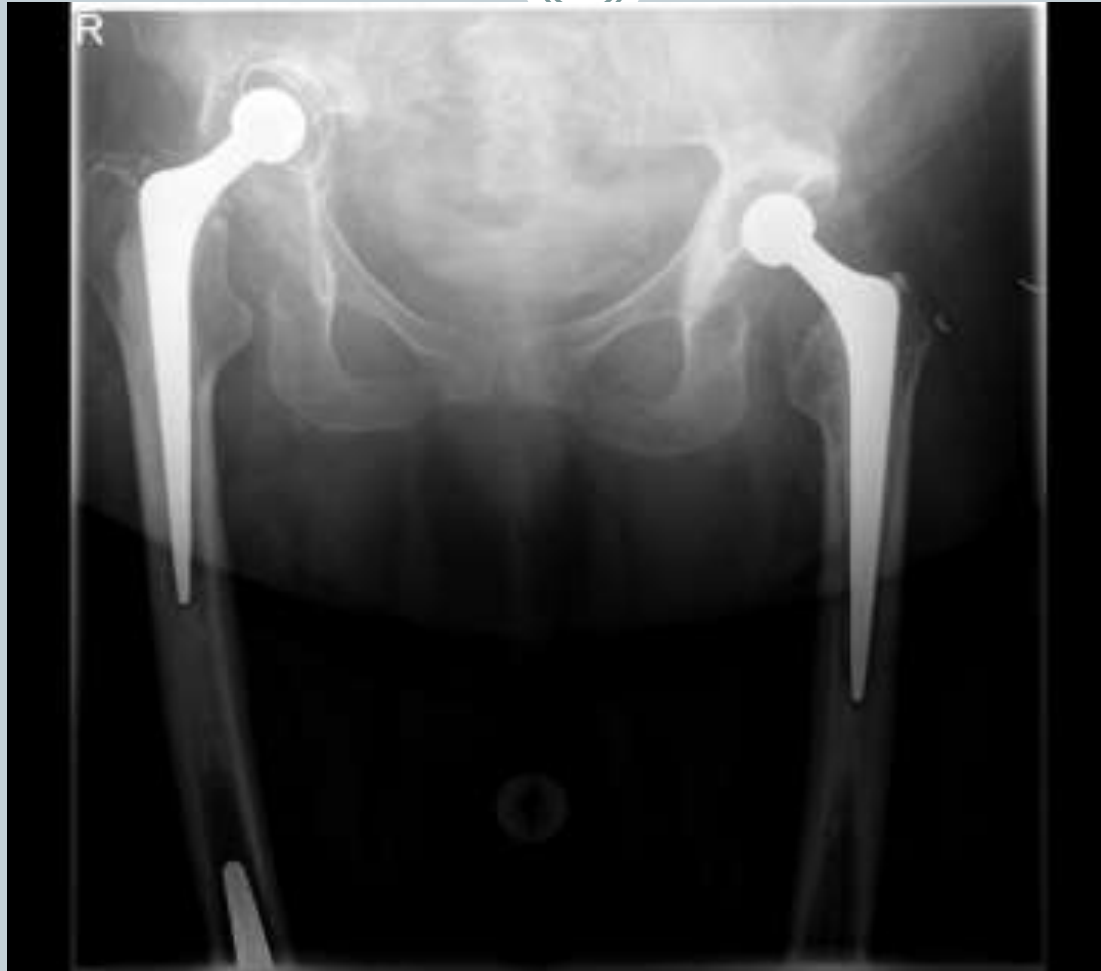- Up asap
- Driving 4-5 weeks
- Physio and exercises
- Normal gait 3-6 months

Complications

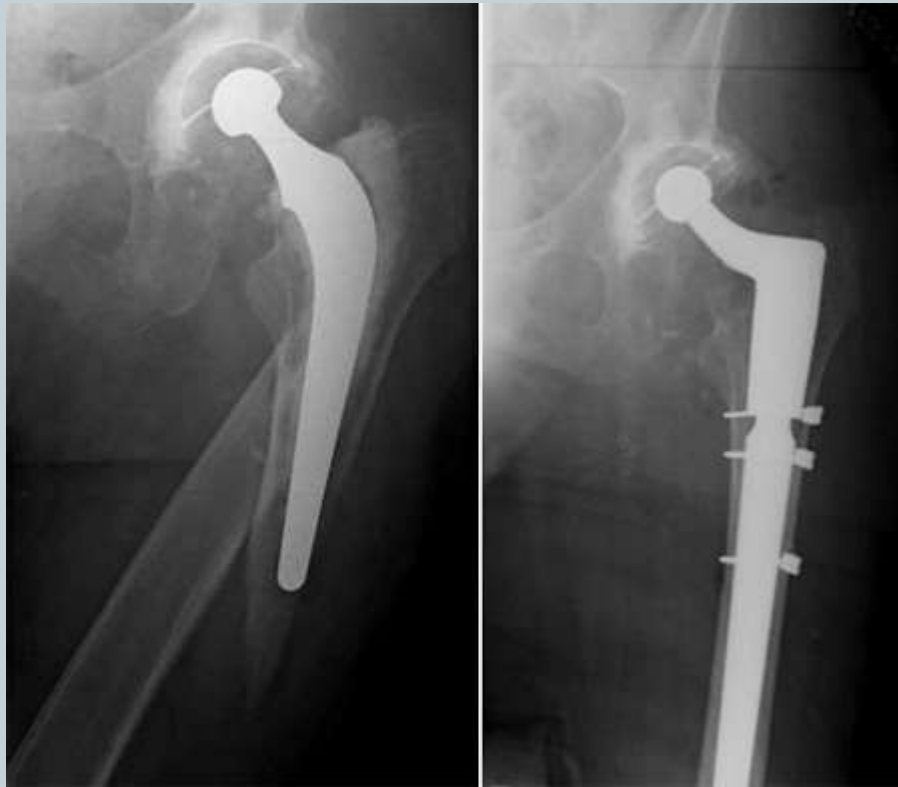

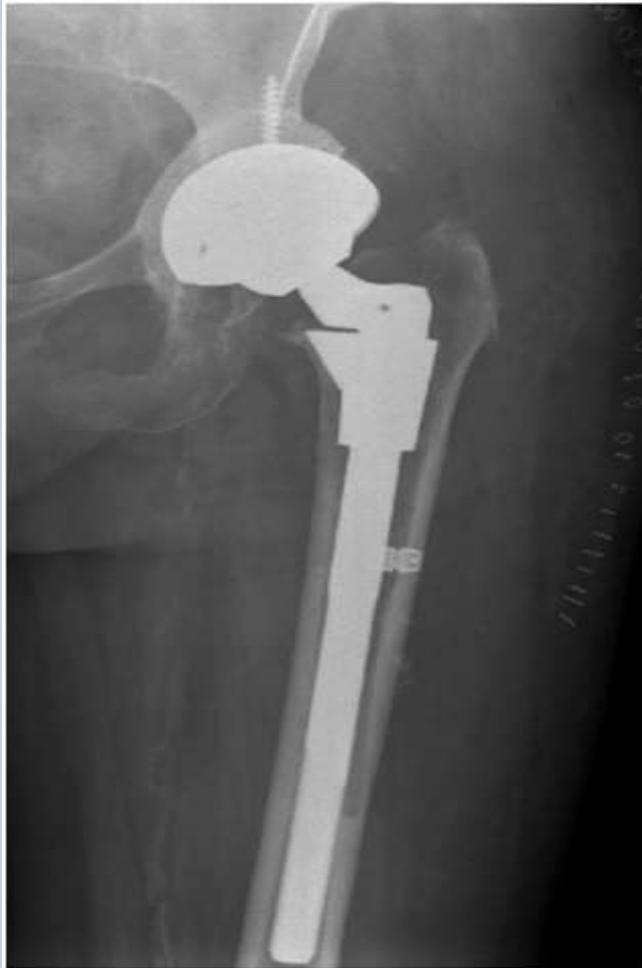- Infection
- Leg length change
- Dislocation
- DVT?PE –blood clots
- Fractures
- Nerve injury
- Loosening
- Wear and tear

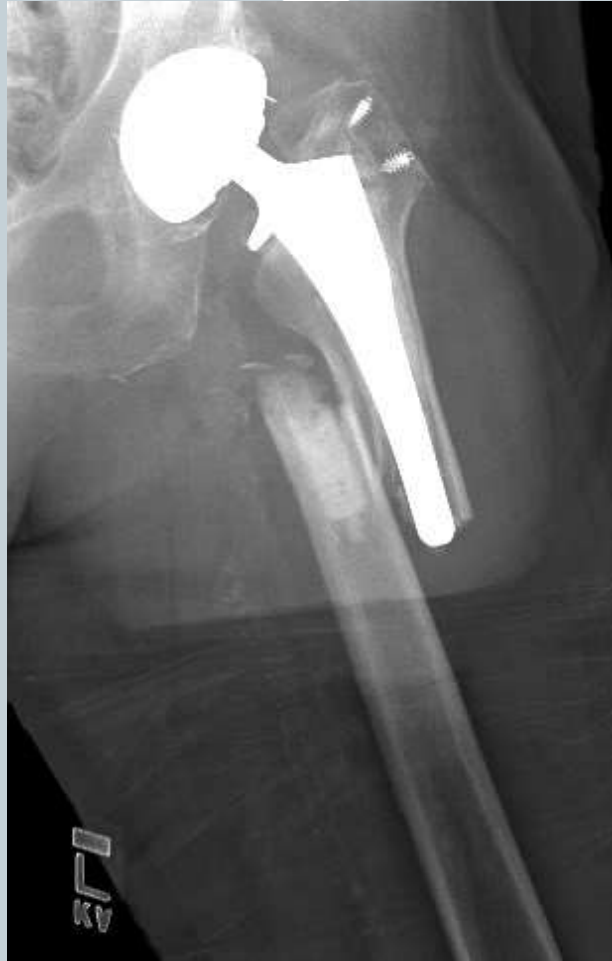Worn Hip Replacement

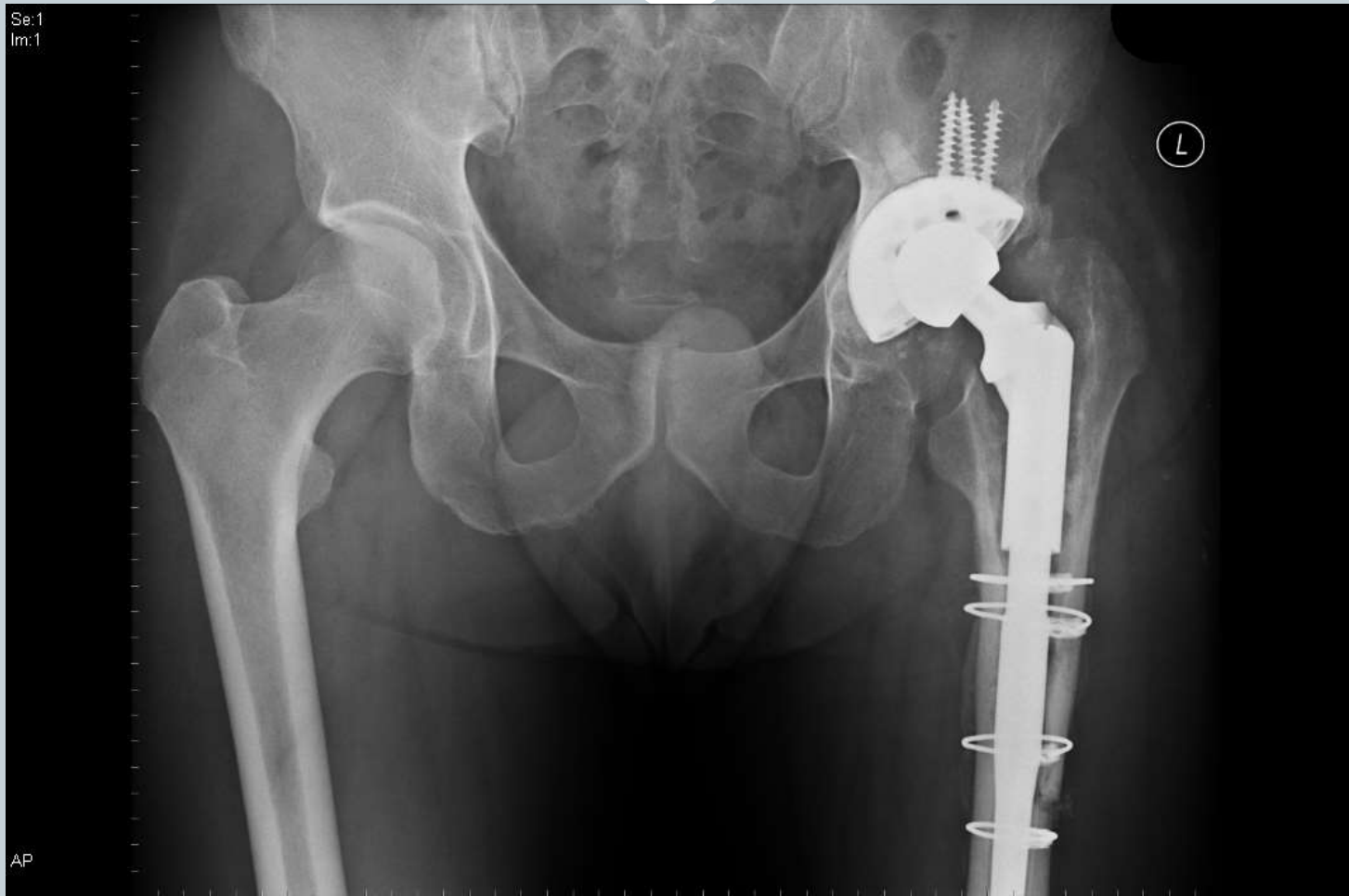

Revision surgery









What's New? Hmm...



- Hip Arthroscopy is mainstream now
- Biomaterials
 - Trabecular metal
 - Ceramics
 - Better plastics

PRP

Increased modularity of THR components

Minimally invasive THR

Short stem THR

Computer Navigated Surgery/ Robotic surgery

Resurfacing of resurfacing!

Advice prior to surgery



- Keep active
- Improve exercise tolerance
- Use that joint – wear it down !
- Joint schools
- A plan for homecoming



THANK YOU

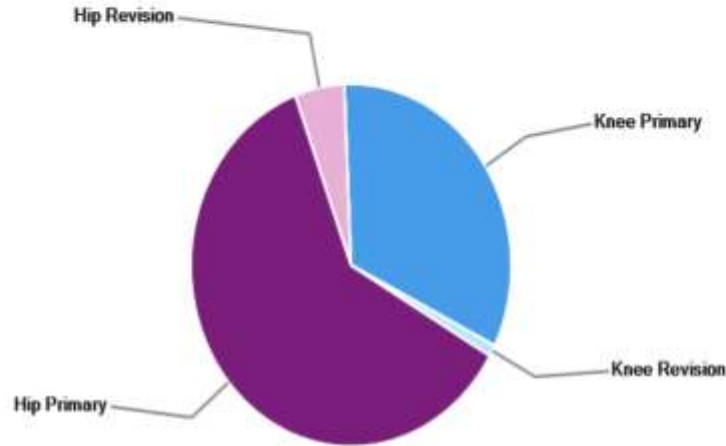


Questions?

Tel: 01883337484 / 01293 785511

E-mail: hipandkneespecialist@gmail.com

Data for 1 April 2019 - 31 March 2022



Operation Type <i>i</i>	Operation Subcategory <i>i</i>	Procedures Recorded for this Surgeon <i>i</i>	National Average <i>i</i>
Hip Primary	-	374	118
Hip Revision	-	30	17
Knee Primary	Patello-Femoral Replacement	Fewer Than 5	6
Knee Primary	Total knee replacement	158	113
Knee Primary	Unicondylar Knee Replacement	43	38
Knee Revision	-	5	13
Total	-	610+	305

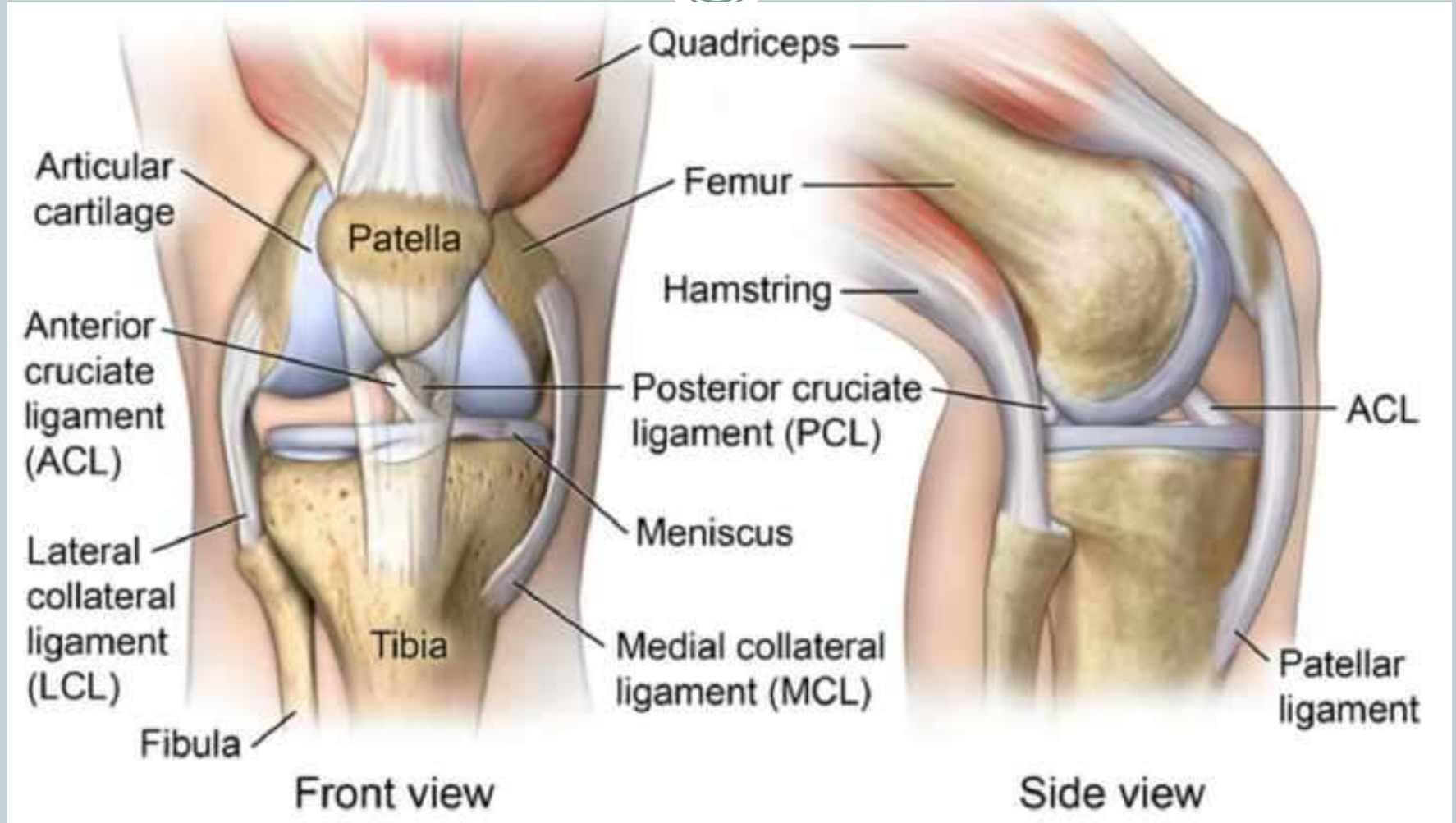
TOP

The Painful or Injured Knee



- History / patient profile
- Trauma/injury/exercise induced
- Mechanical symptoms
 - Locking/catching/giving way/clicking

Knee anatomy

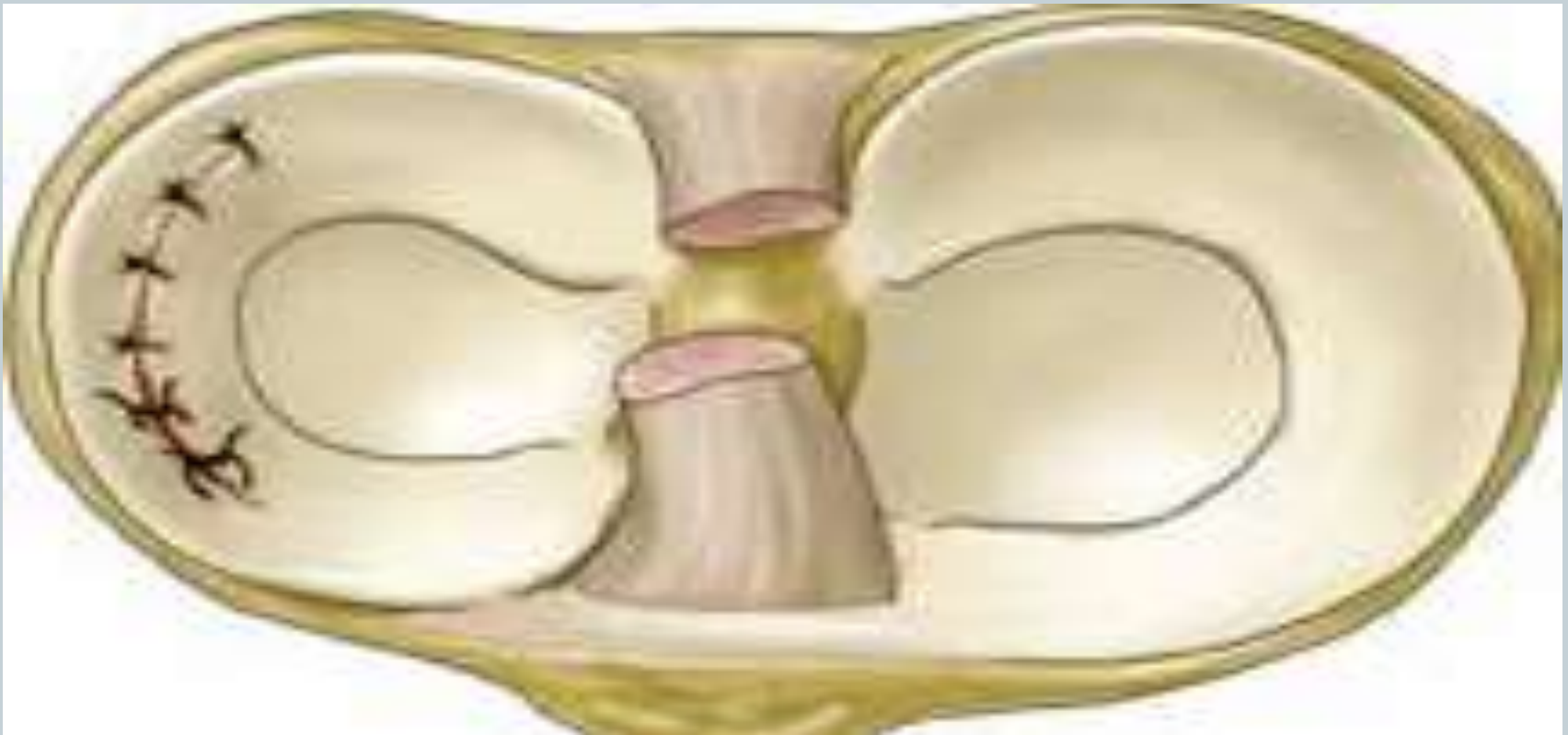

Knee Examination (real world)

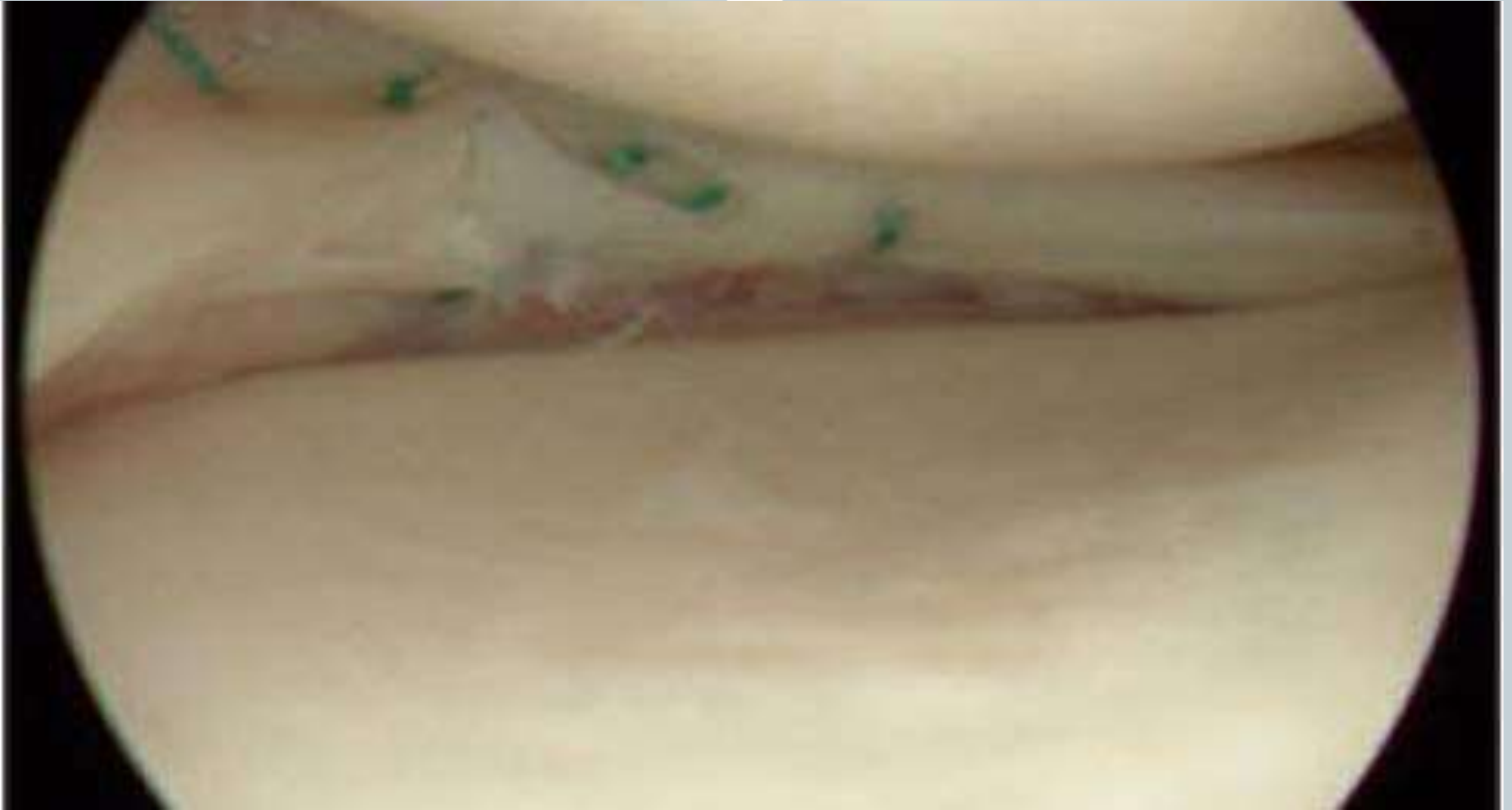


- Watch gait- limp/knee flexed/deformity/swelling
- Squat- pain?
- Supine on the couch
 - Any deformity –valgus /varus/ flexion/lumps
- Palpate for areas of tenderness and muscle ligament attachments
- Palpate joint line
- Can they straight leg raise?
- Special tests for stability and meniscal pathology
- Check hip !
- And distal circulation and sensation

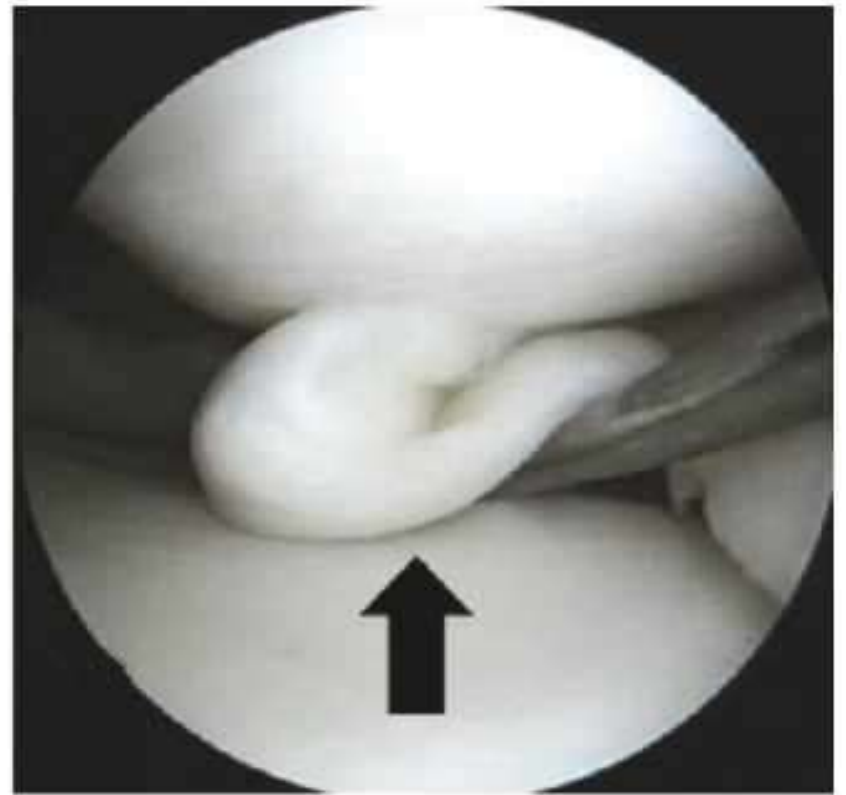
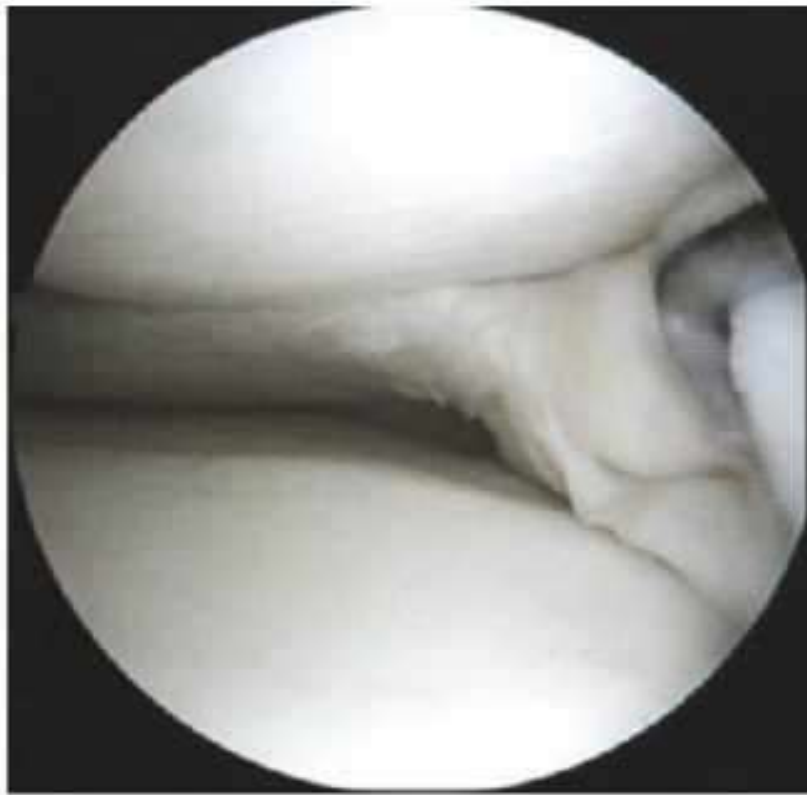Meniscal repair



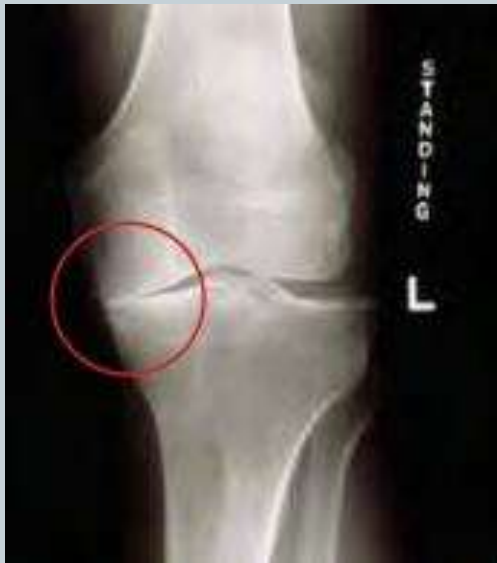Meniscal repair



Meniscal tear

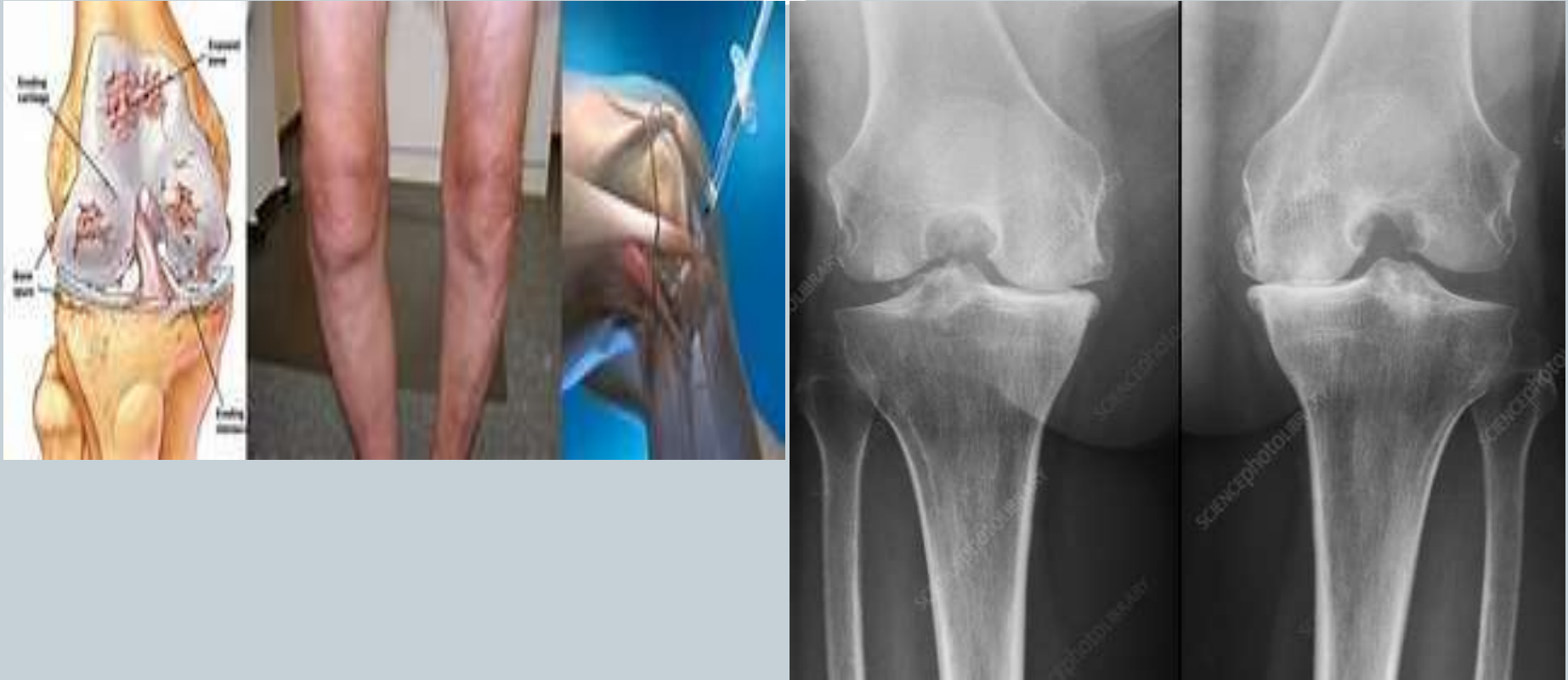

Knee OA



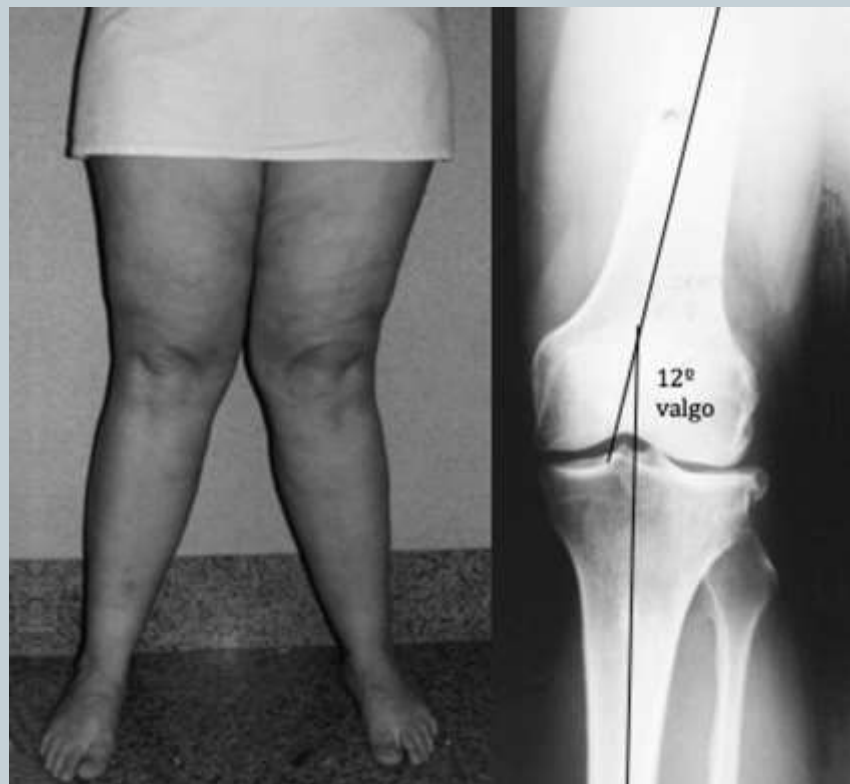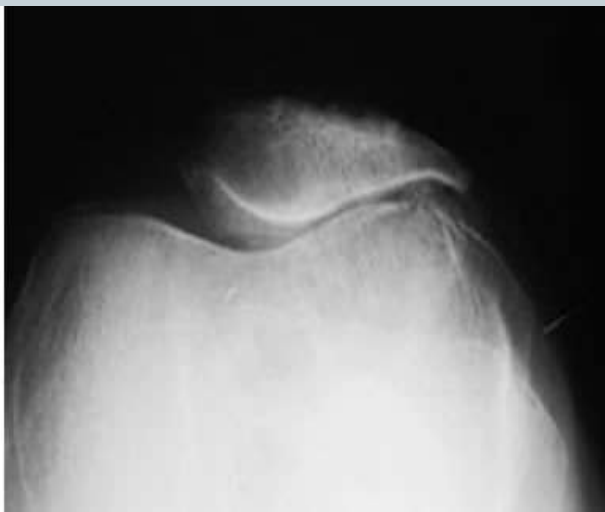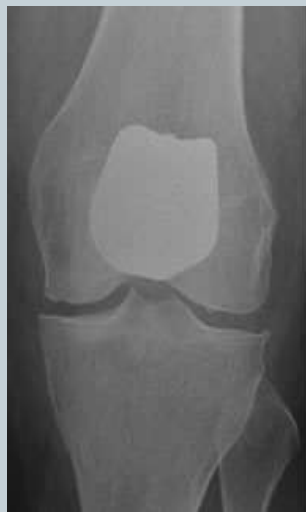- Medial OA

Knee arthritis

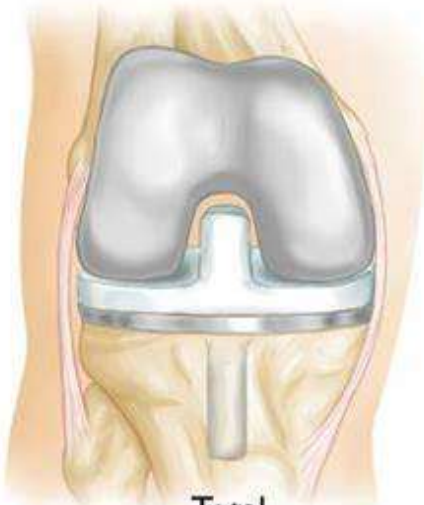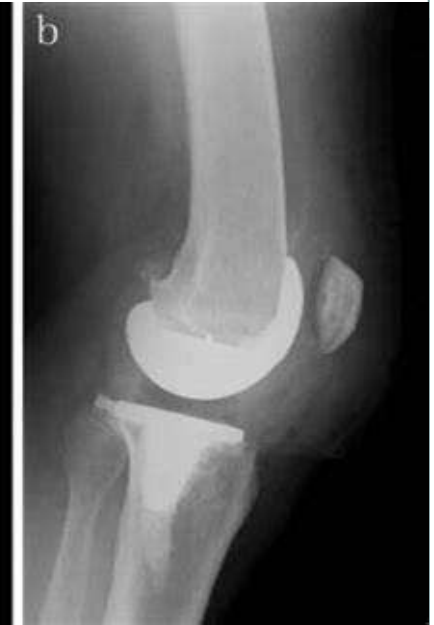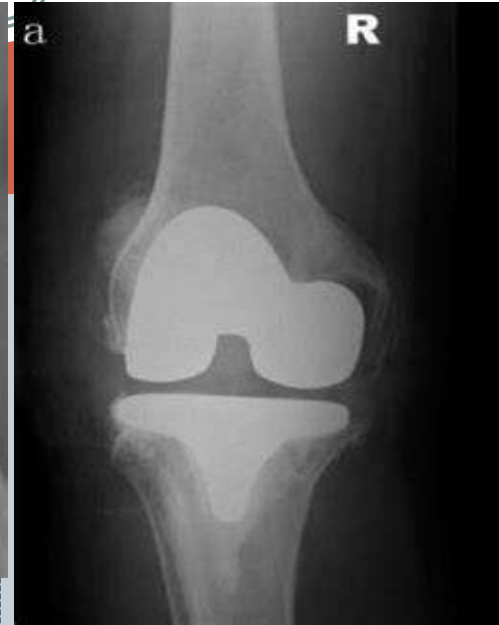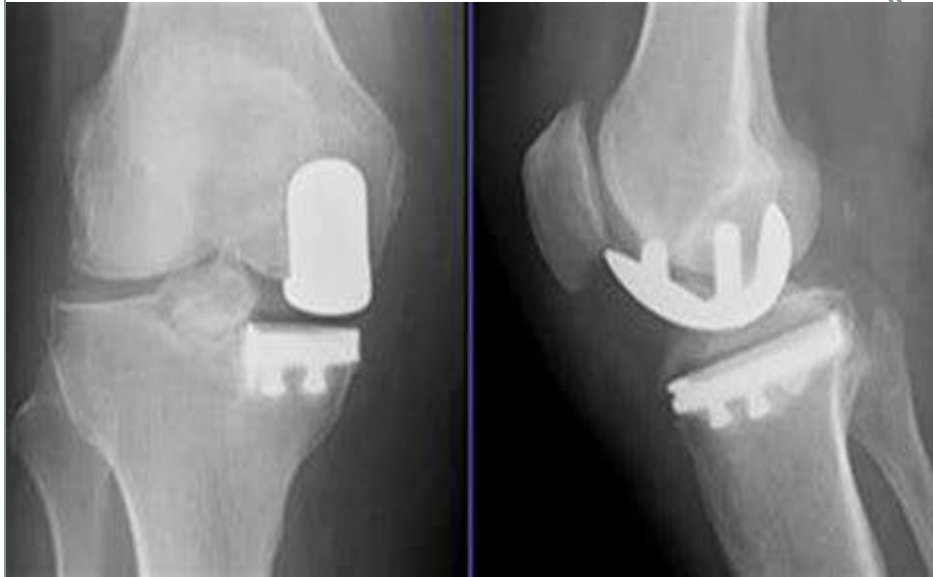




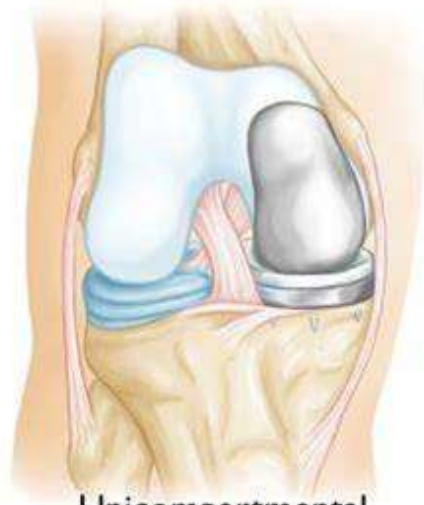Patellofemoral OA



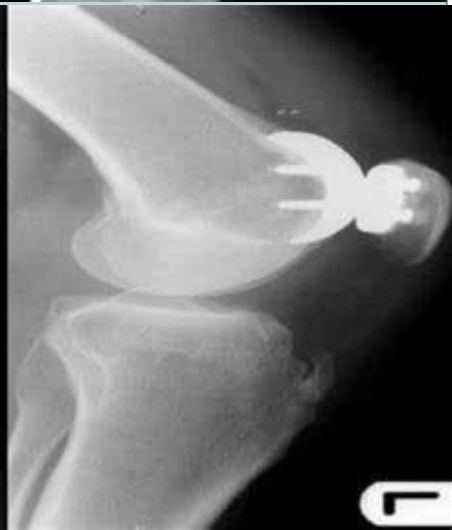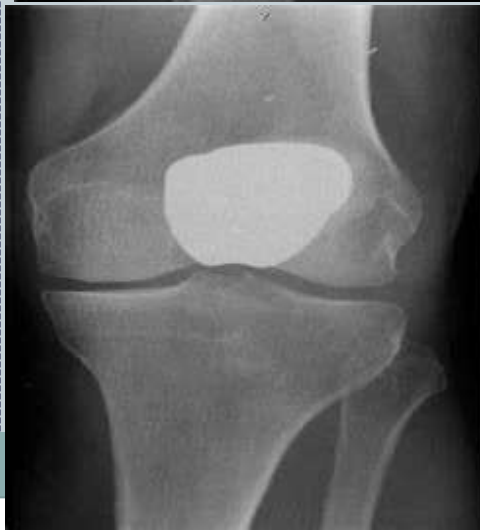Knee replacement



Total



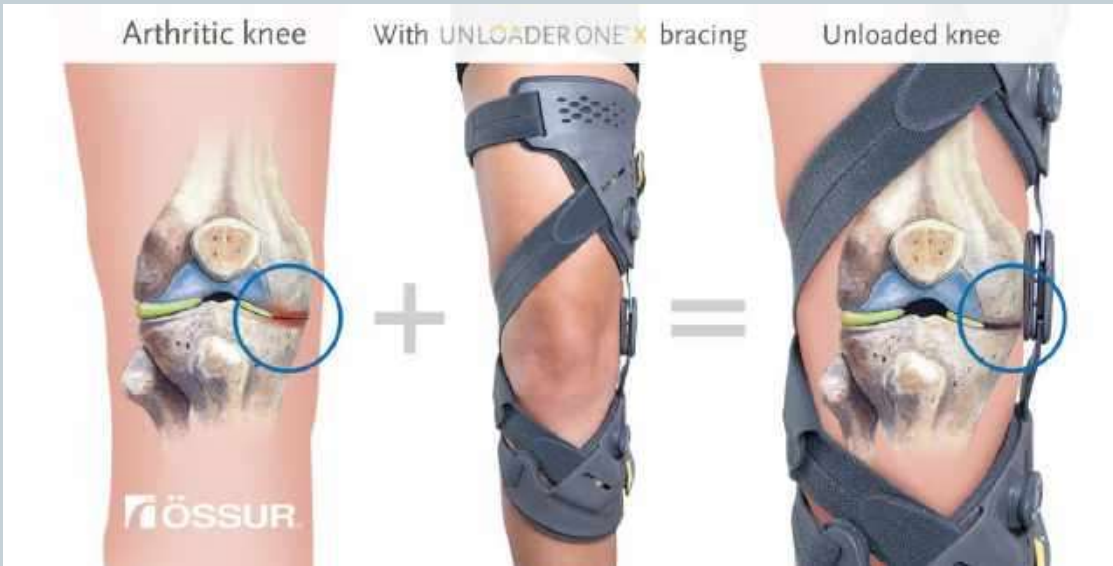Unicompartmental



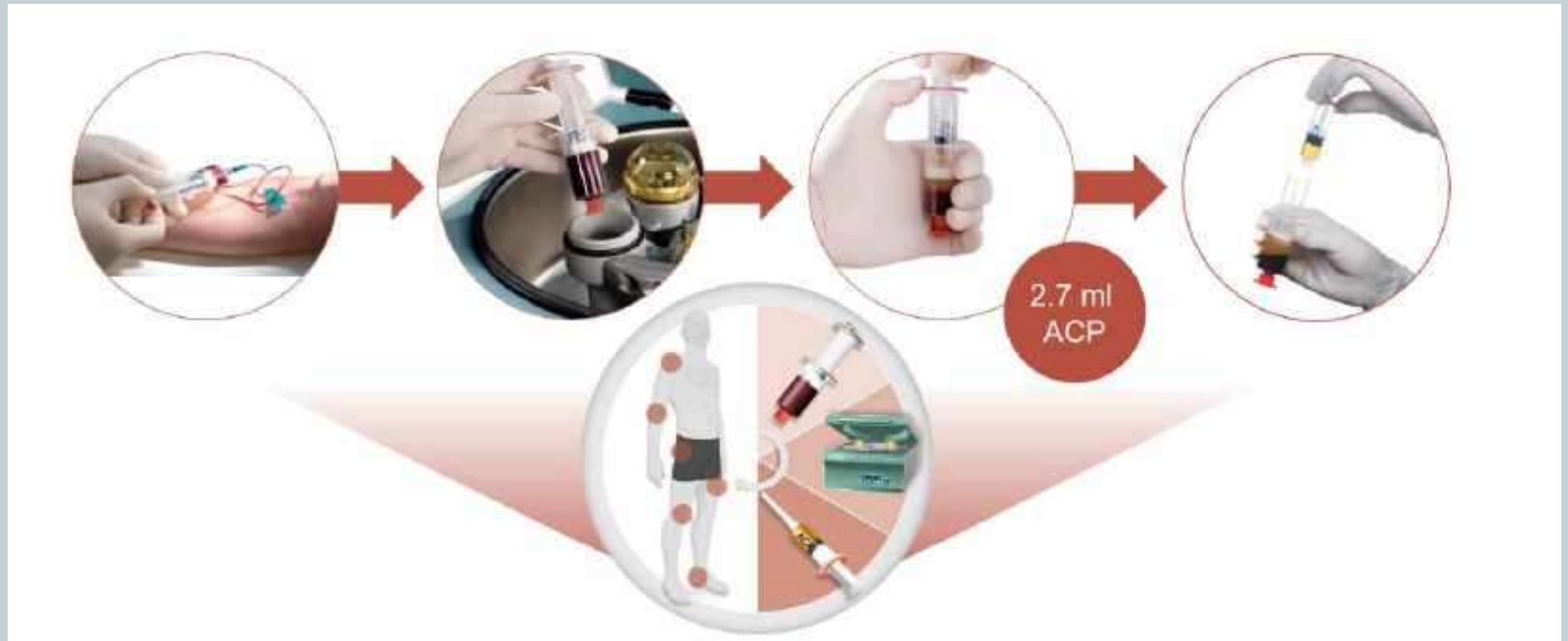Knee preservation in early OA

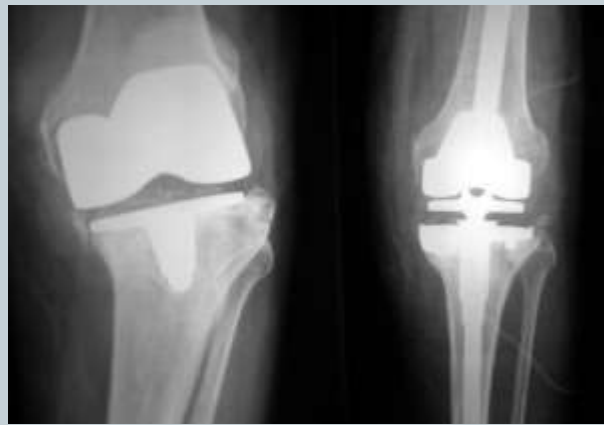

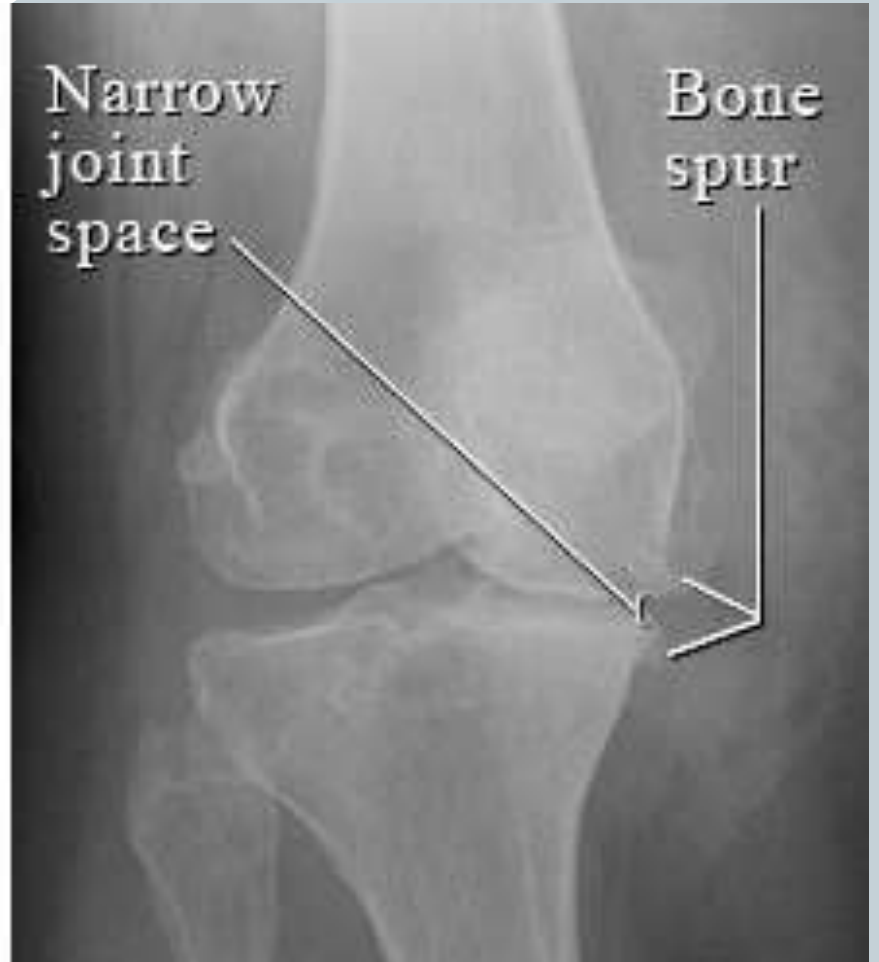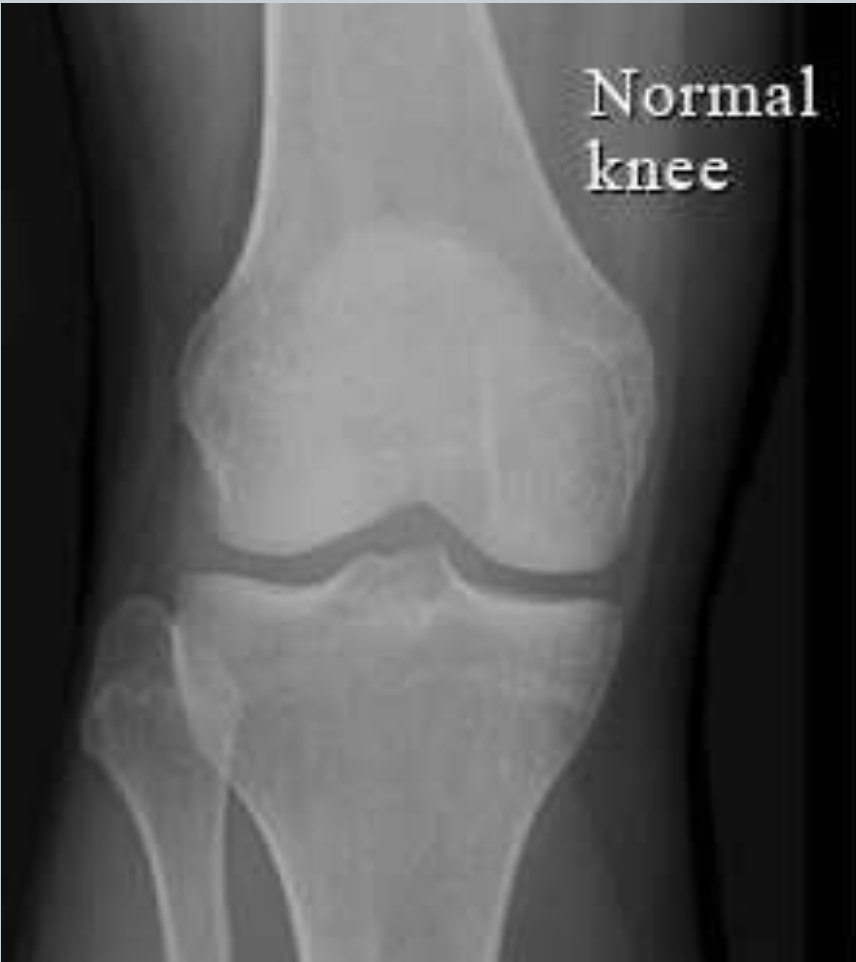- Weight and activity modification
- Physiotherapy
- Gait and orthotics
- Cartilage supplements/antioxidants
- Offloader braces
- PRP –Platelet rich plasma
- Hyaluronidase
- Steroids – limited role



PRP – Platelet rich plasma





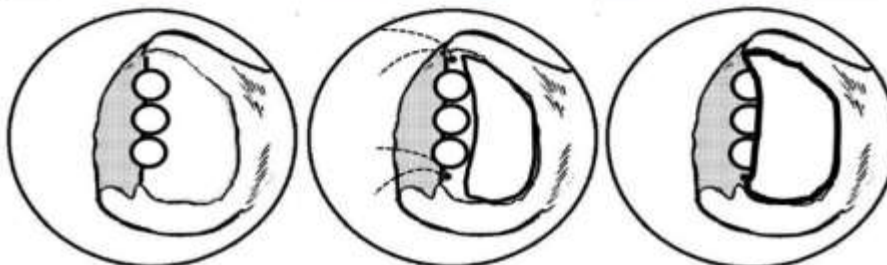
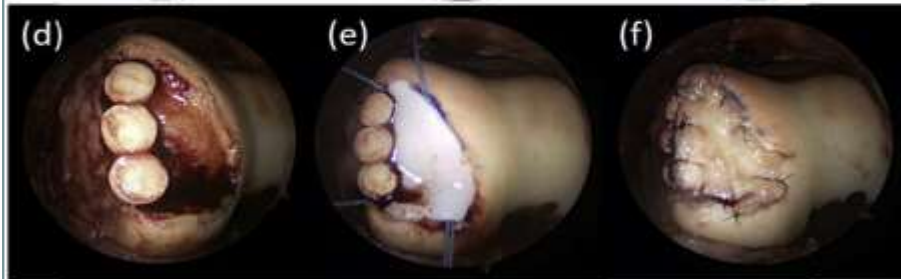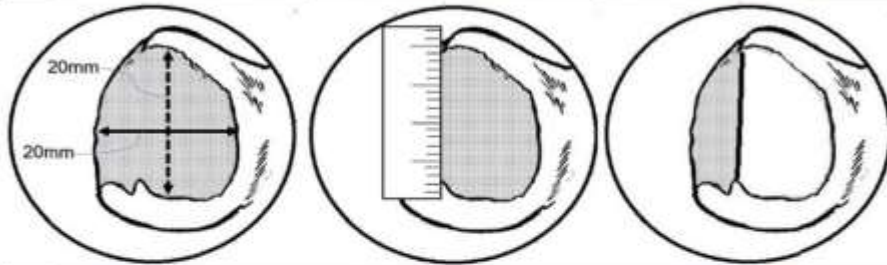
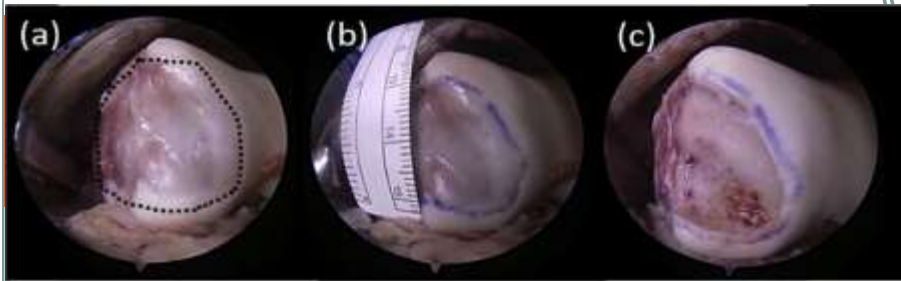


Options for cartilage Loss



- Debridement
- Microfracture
- Mosaicplasty
- ACI / MACI
- Stem Cell Therapy
- Chondral guide patches
- Biomechanical options
- Osteotomy
- Partial replacements
- Total replacements

Osteochondral defect (massive pothole in knee cartilage)



- Surgical treatment

Whats new?



- ACI / MACI
- Stem Cell Therapy
- Chondral guide patches
- PRP
- Knee replacement designs
- Variations of ACL reconstruction techniques

The Future ?

Maybe more preventive

genetic manipulation/ pharmacological

Thank You



Questions?

- Happy knees take some doing!

